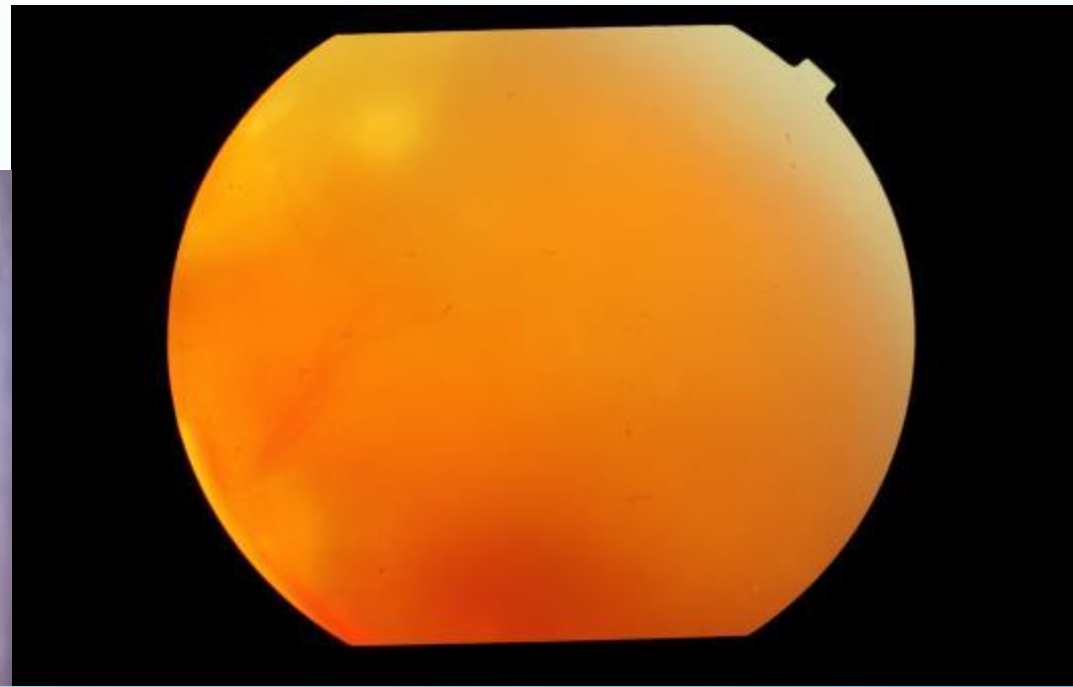
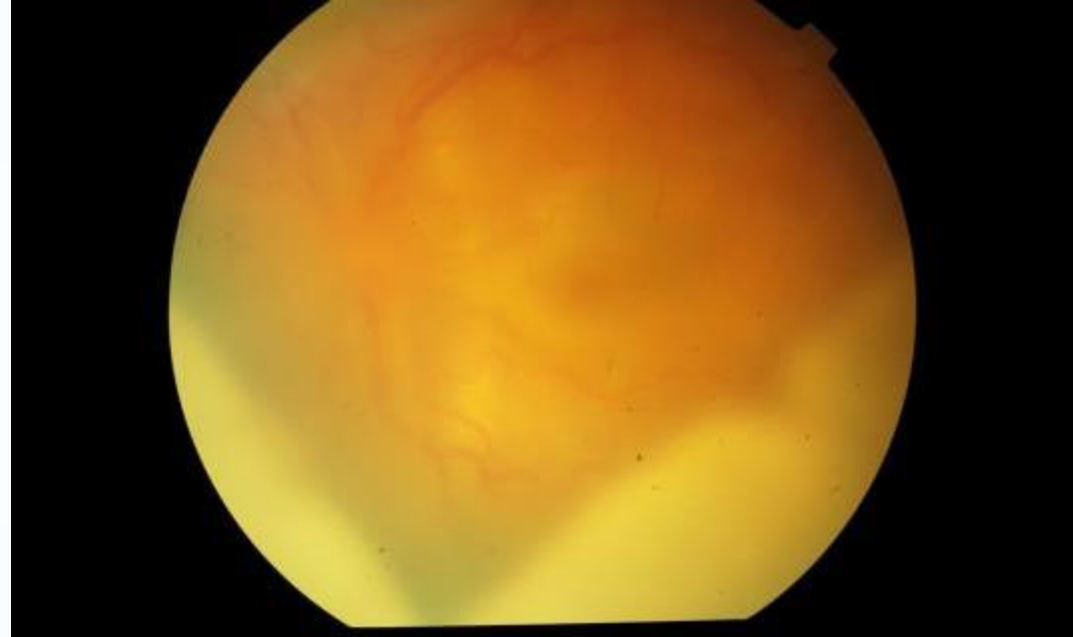


# CASE 1

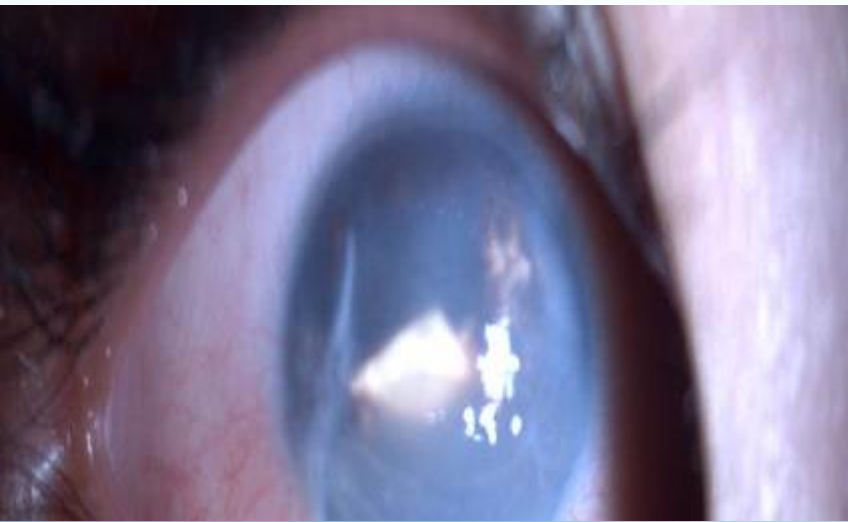DR MONICA SAMANT  
LAXMI EYE INSTITUTE  
MUMBAI (INDIA)

3 yr old female presented with decreased vision in left eye.

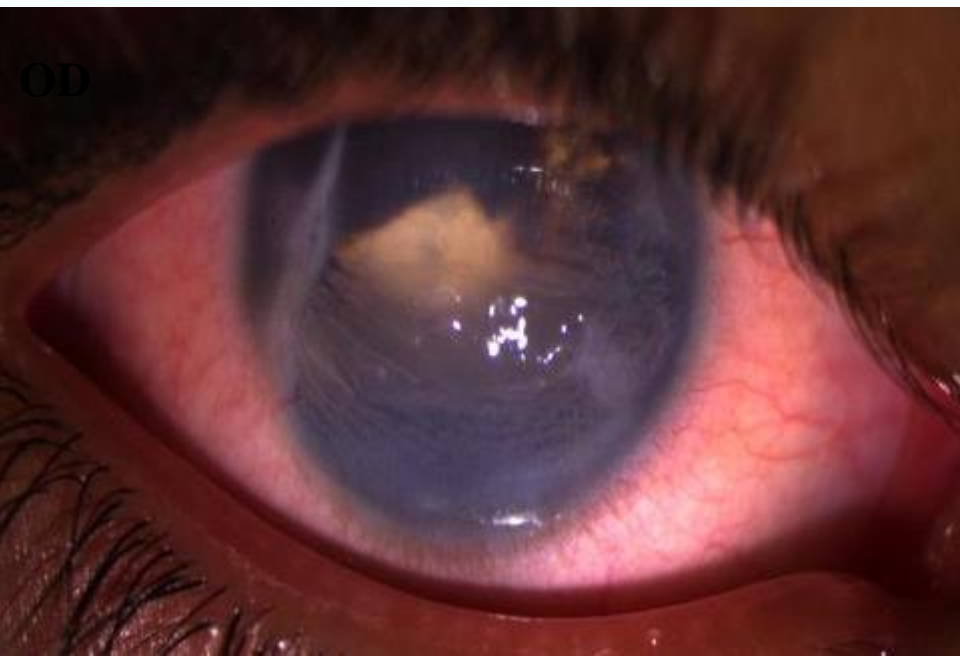
OD s/p repair for penetrating trauma one month ago elsewhere.



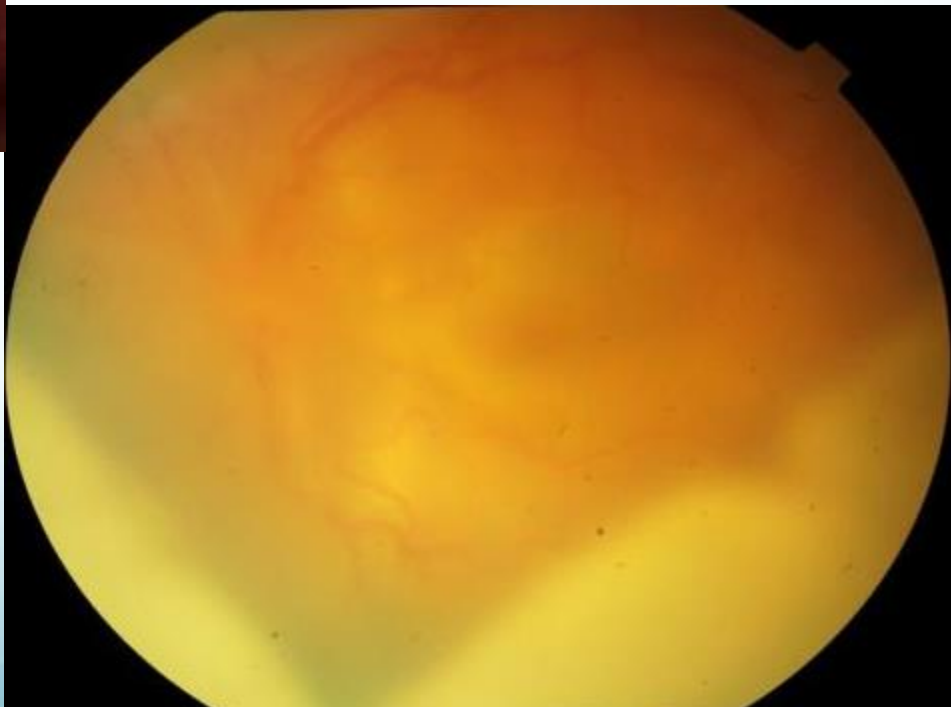
**OD**



**ON EXAMINATION - RE**  
**Vn - PL**



**ON EXAMINATION - LE**  
**Vn - CF – Close to Face**  
**AC – Thick Membrane in AC**  
**Posterior Segment – Hazy media**

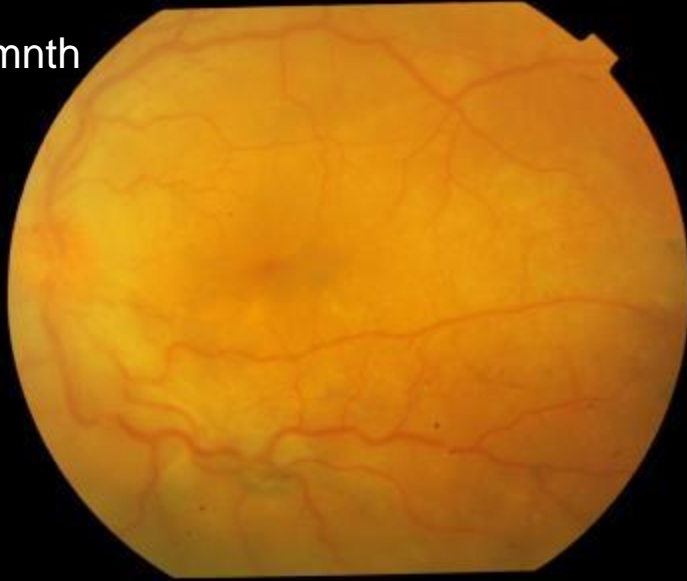

**B – Scan – LE – choroidal thickening**

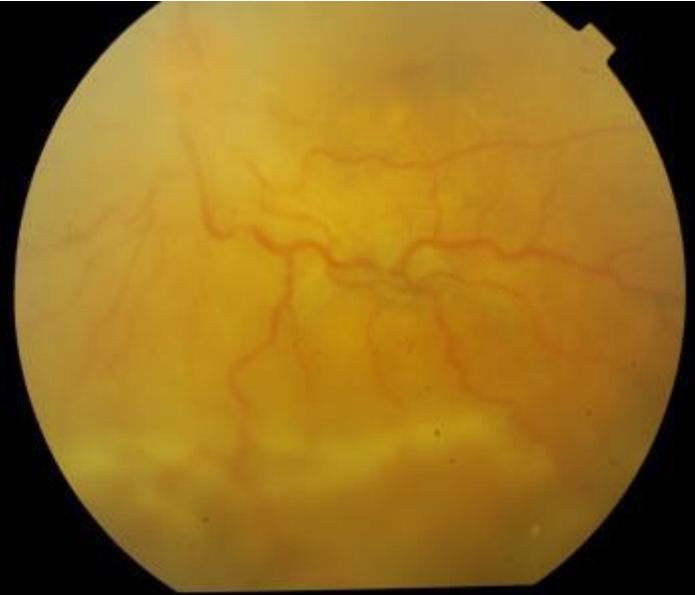**LE – Sympathetic Ophthalmia**

# Treatment : systemic and local immunosuppression

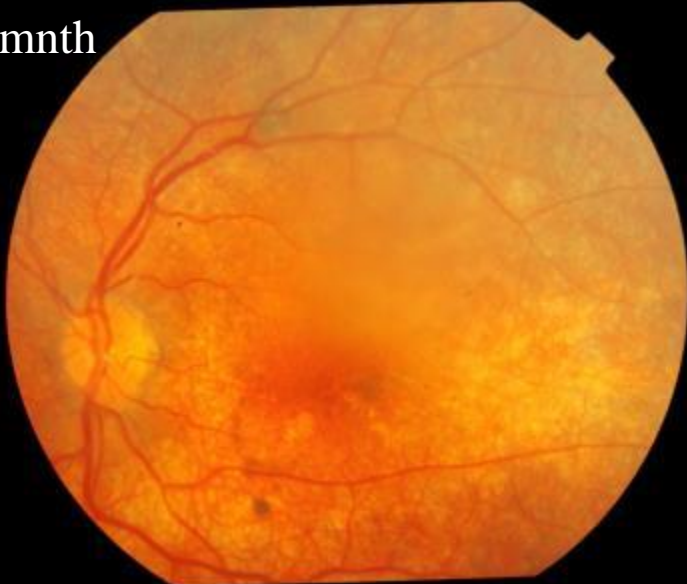At 1mnth



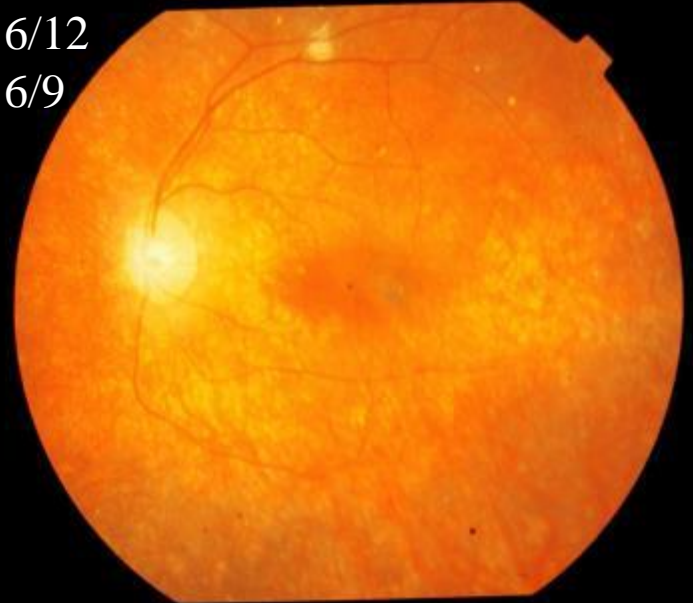Vn  
6/36



At 6mnth

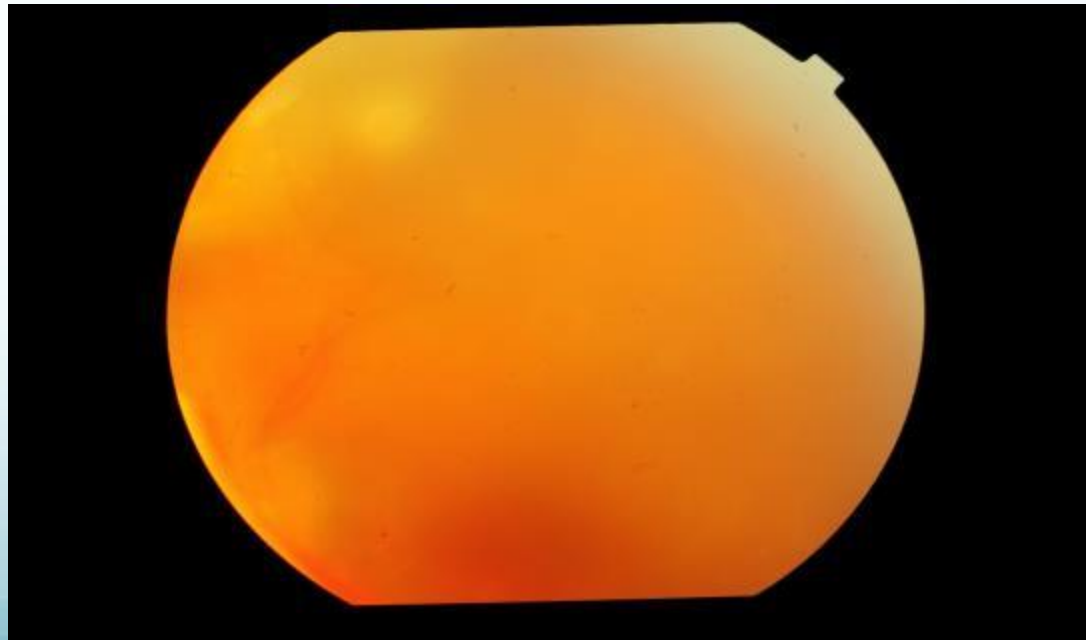
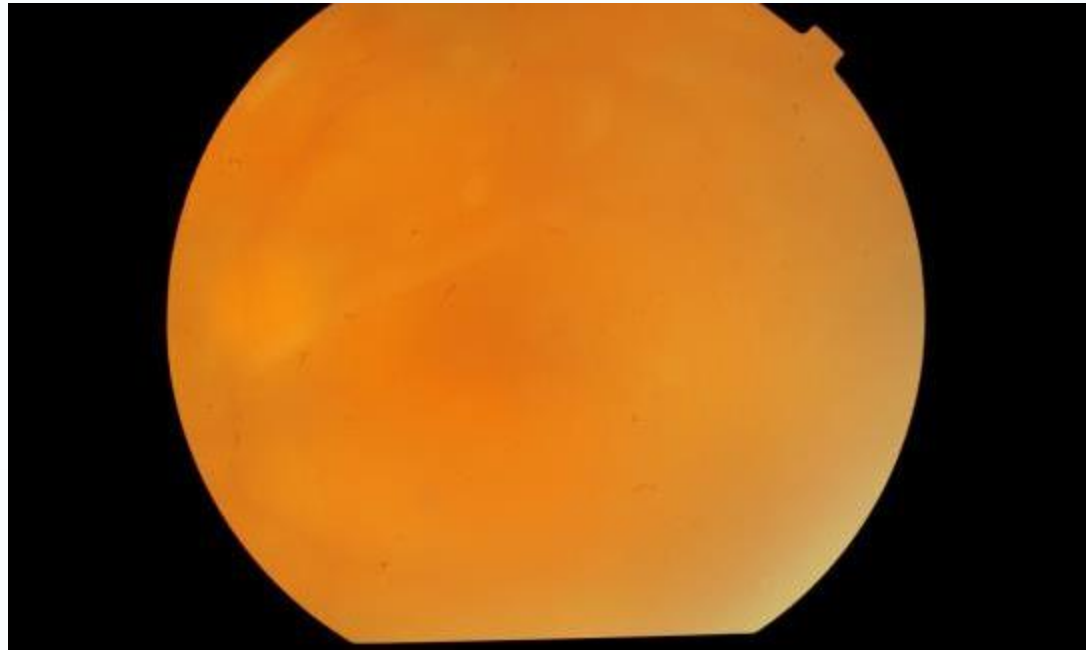


Vn 6/12  
Nv 6/9



Lost to follow up came after  
six months.

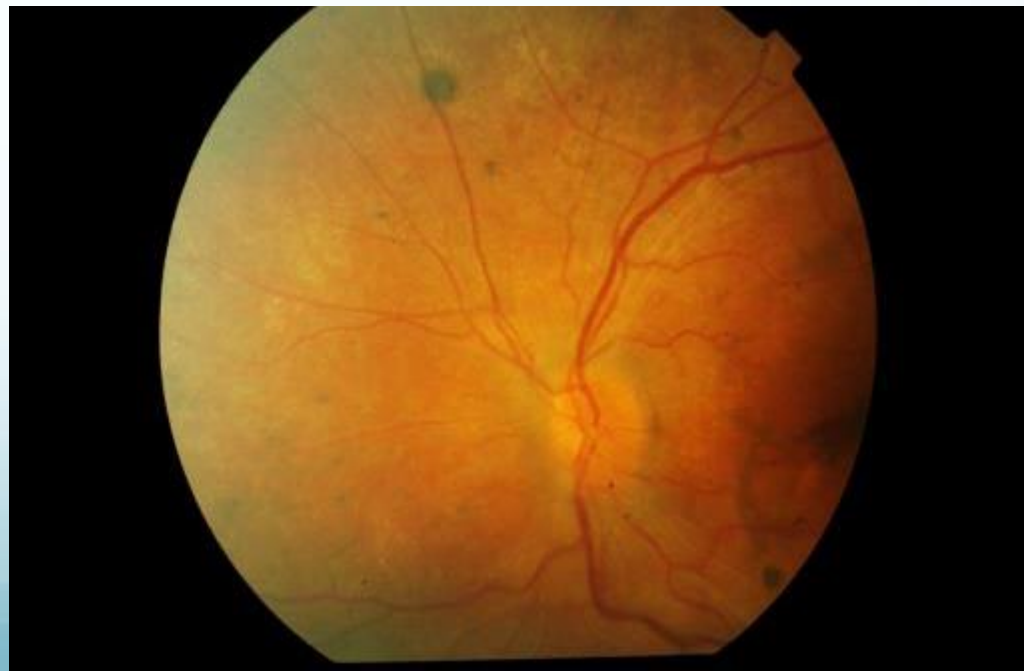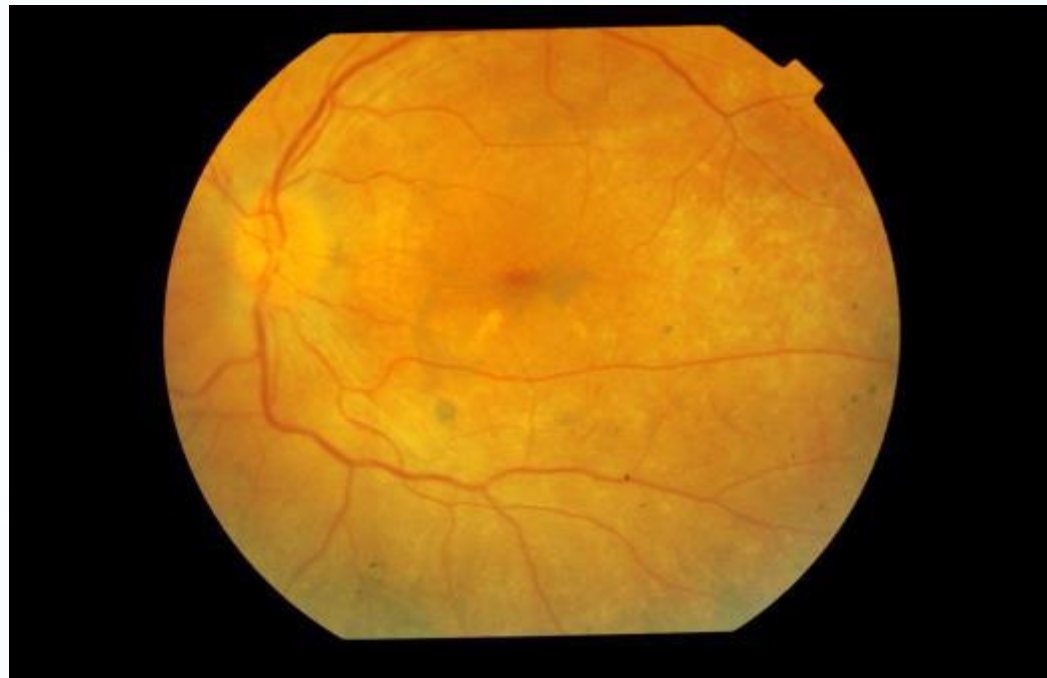Time from first visit – 1 yr

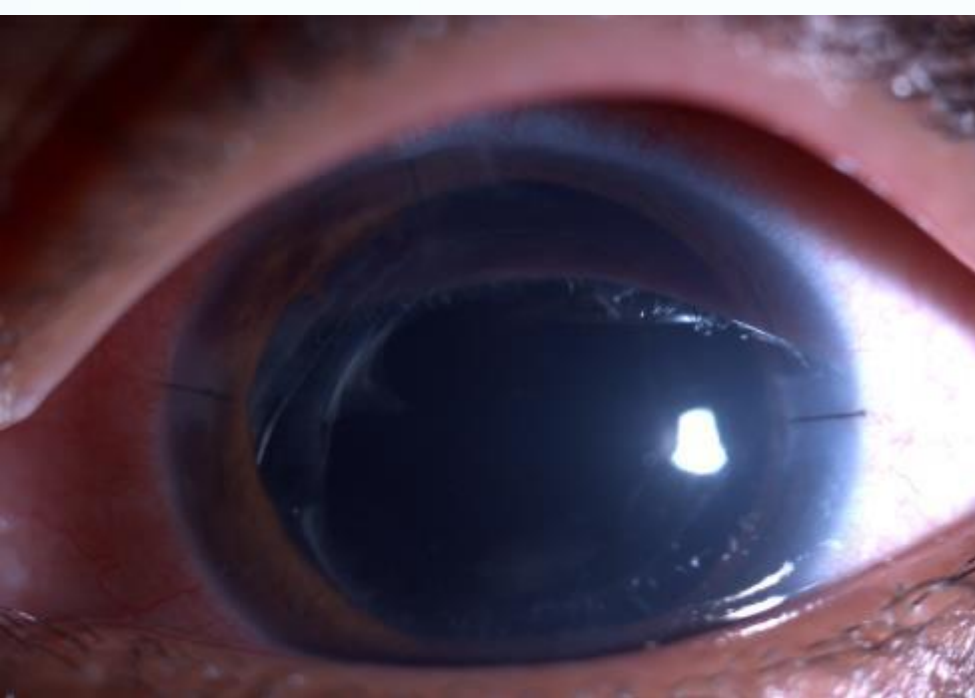


Eleven months after the  
Retreatment

New issues: Cataract

Time since first visit—2 yrs





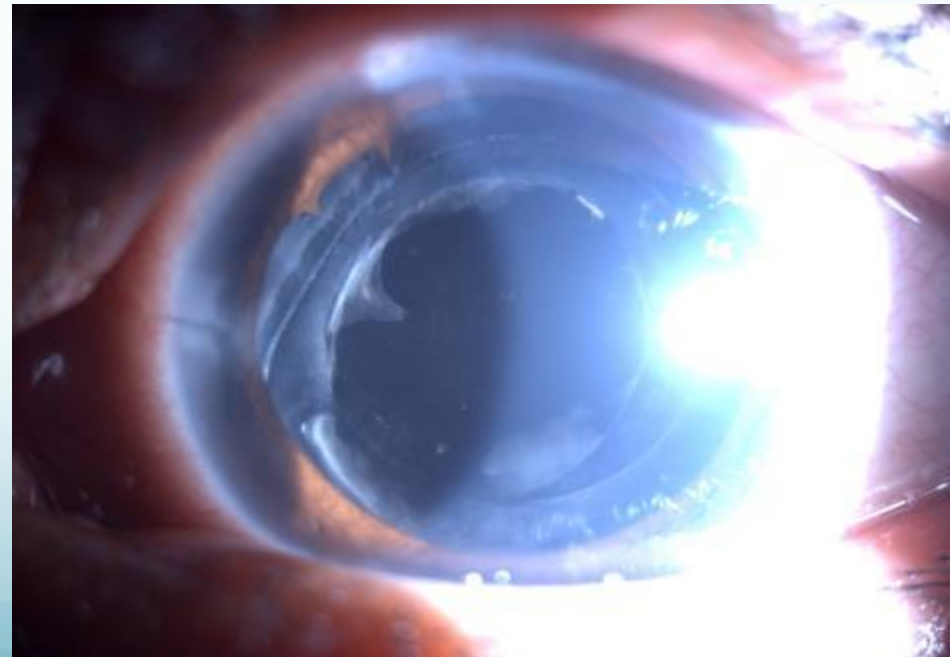
- S/p cataract surgery.
- VA; 6/12 Nv 6/6.
- Treatment: systemic and local immunosuppression which was tapered over six months.
- During this period patient presented with high IOP hence started on anti glaucoma medication

**CURRENT**

VN: 6/36

MEDICATION : topical steroid once daily ,topical antiglaucoma , and oral diamox.

No systemic immunosuppression .



## CURRENT CHALLENGES :

PCO

GLAUCOMA : Persistent raised IOP  
with increase in cup : disc ratio

WHAT NEXT?

YAG...FOLLOWED BY TRAB?

TRAB...FOLLOWED BY YAG?

YAG...FOLLOWED BY ANY OTHER  
OPTION FOR GLAUCOMA?

