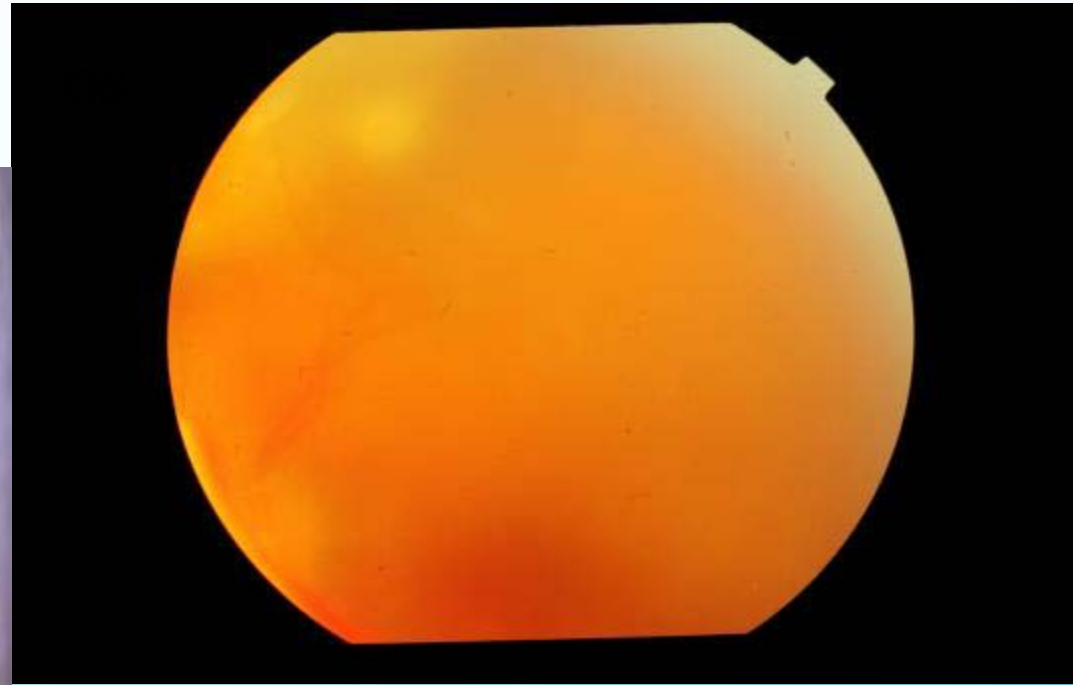
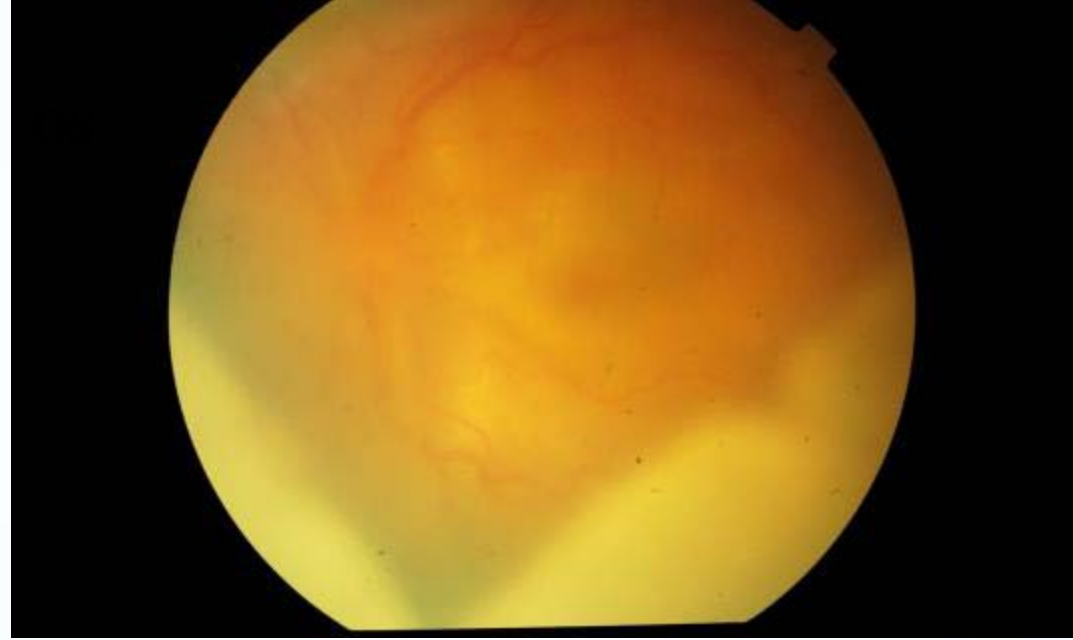

CASE 1

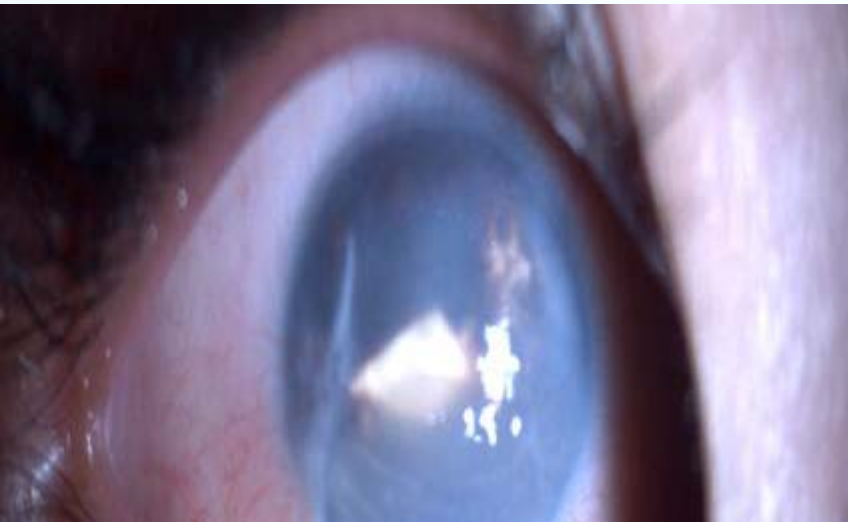DR MONICA SAMANT
LAXMI EYE INSTITUTE
MUMBAI (INDIA)

3 yr old female presented with decreased vision in left eye.

OD s/p repair for penetrating trauma one month ago elsewhere.

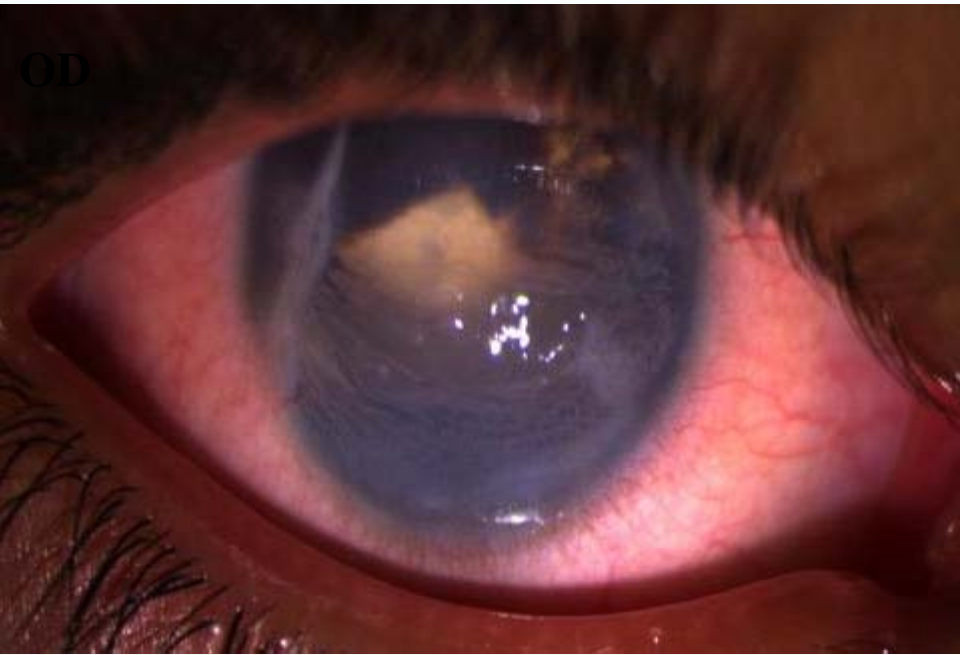


OD



ON EXAMINATION -RE

Vn - PL



ON EXAMINATION - LE

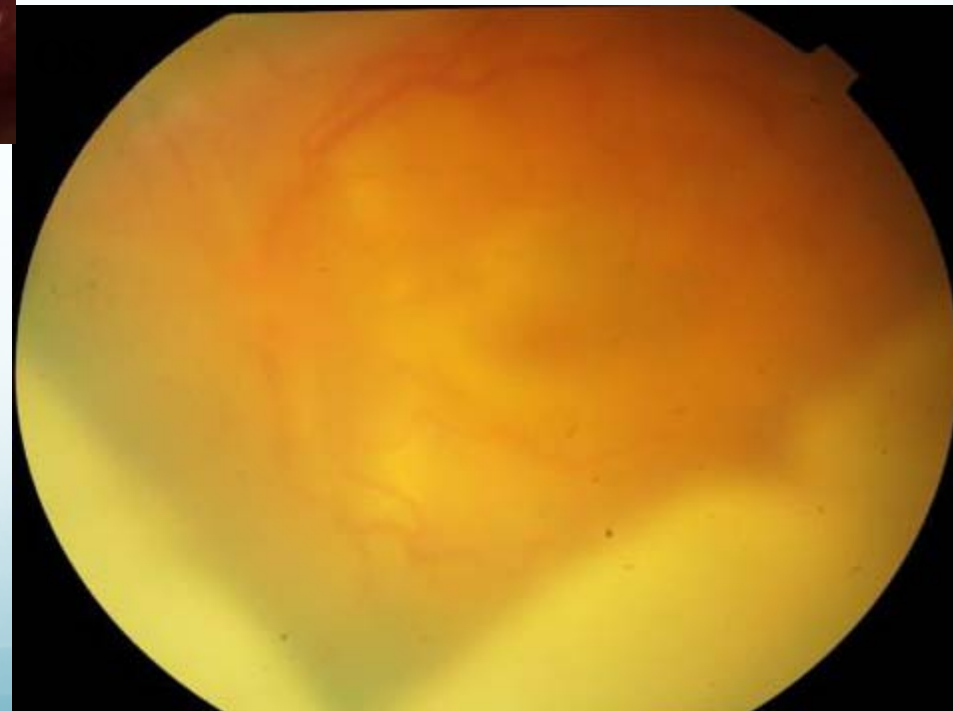
Vn - CF – Close to Face

AC – Thick Membrane in AC

Posterior Segment – Hazy media

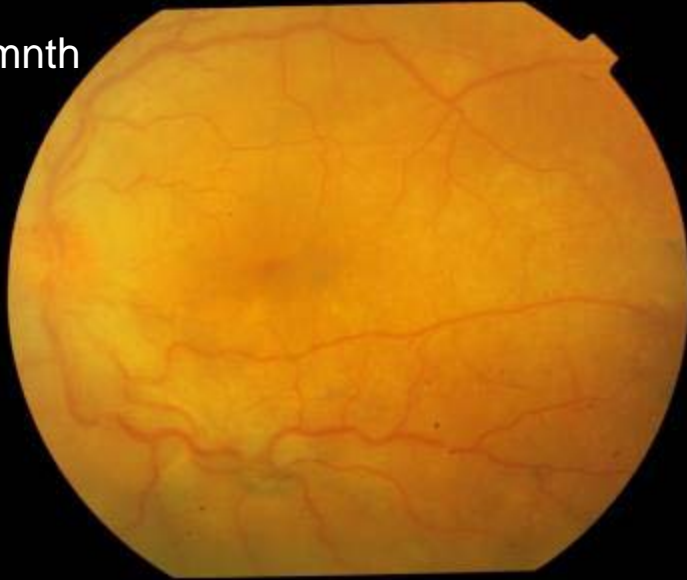B – Scan – LE – choroidal thickening

LE – Sympathetic Ophthalmia

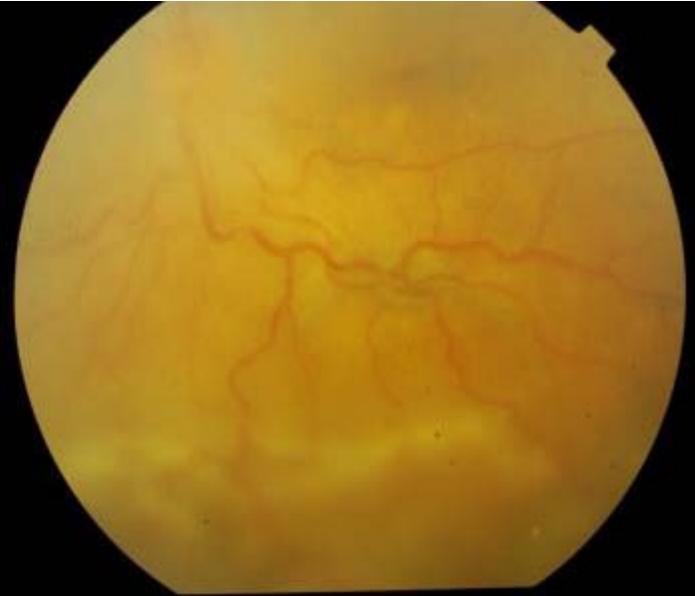

Treatment : systemic and local immunosuppression

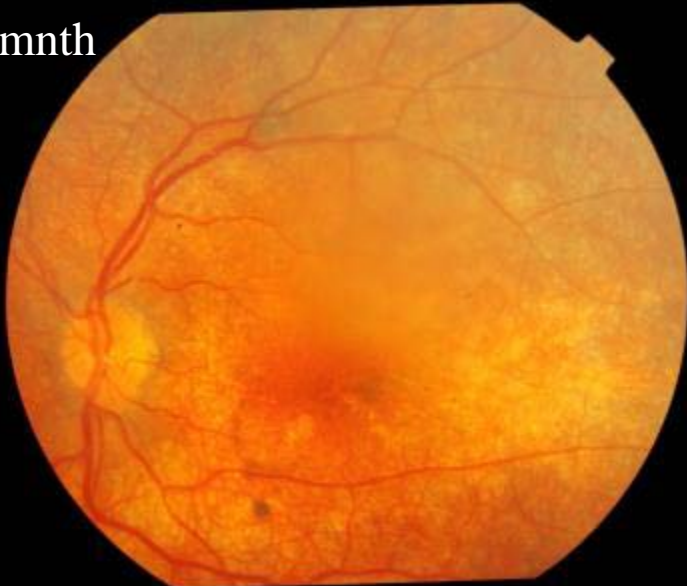At 1mnth



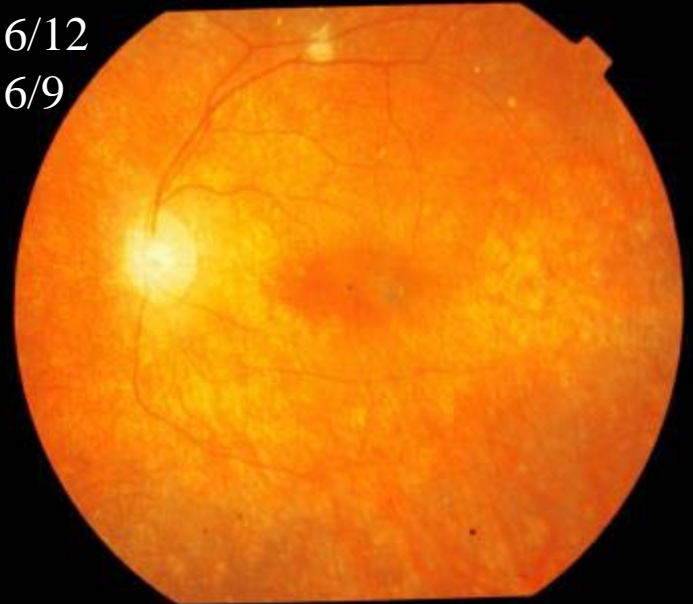Vn
6/36



At 6mnth

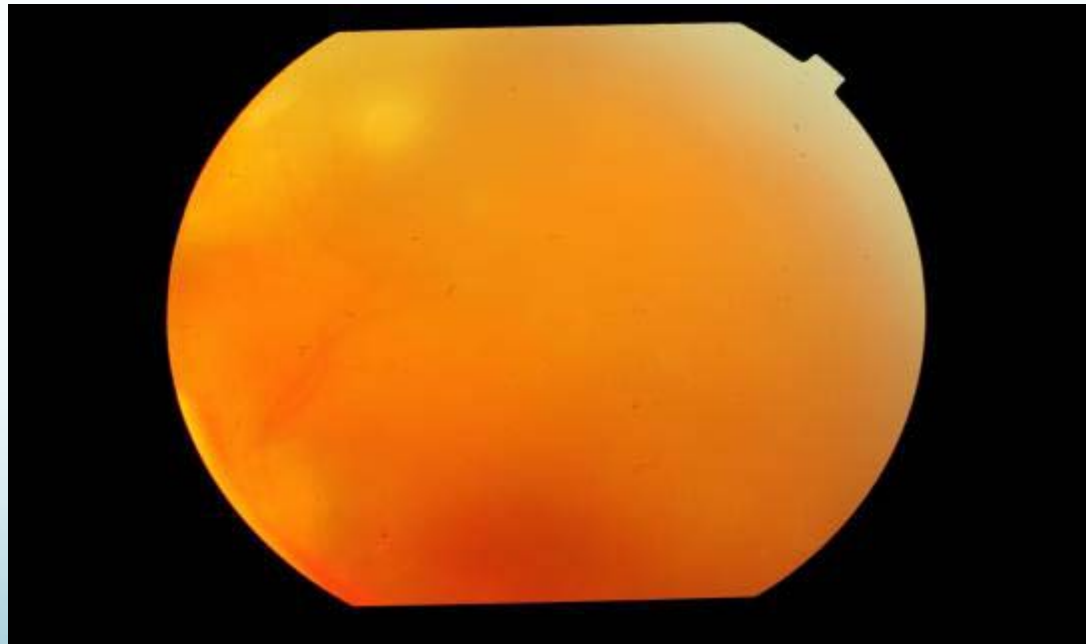
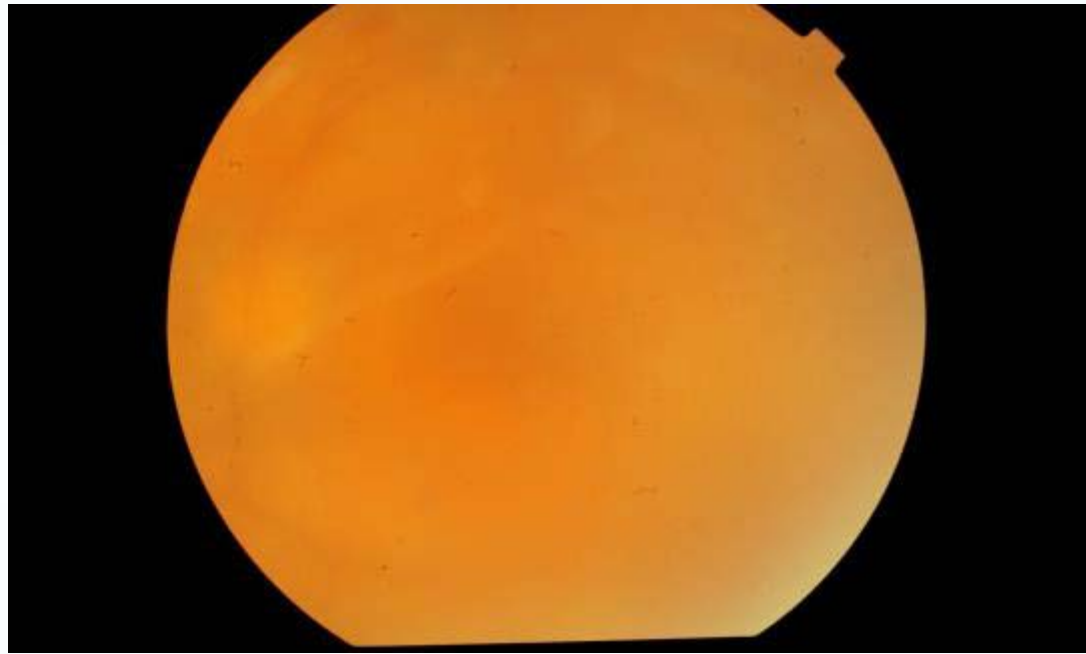


Vn 6/12
Nv 6/9



Lost to follow up came after
six months.

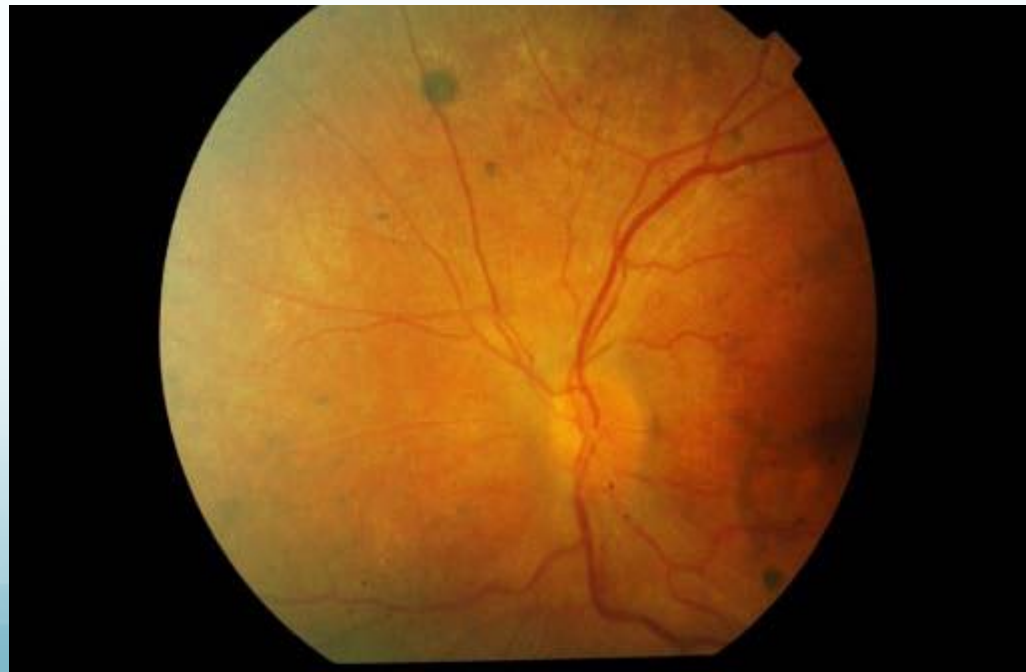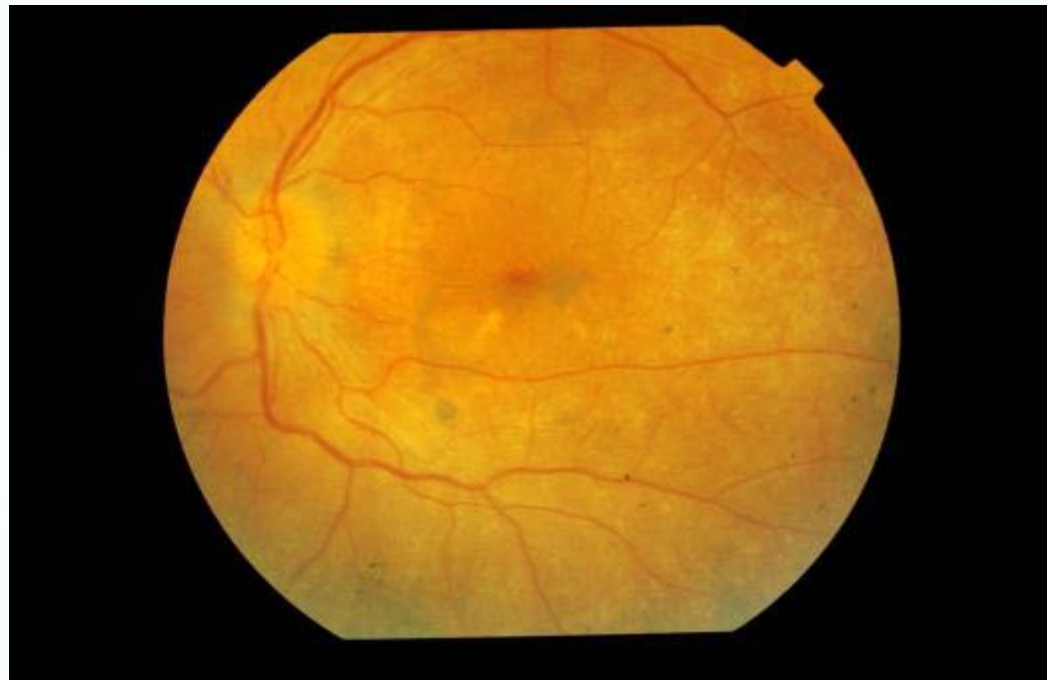Time from first visit – 1 yr

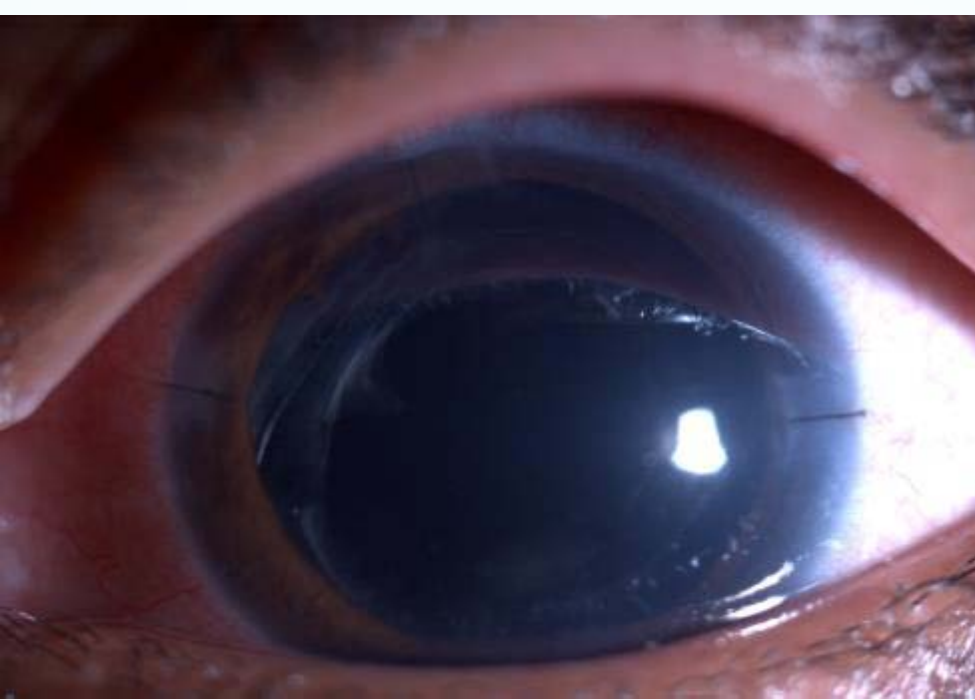

Eleven months after the
Retreatment

New issues: Cataract

Time since first visit—2 yrs





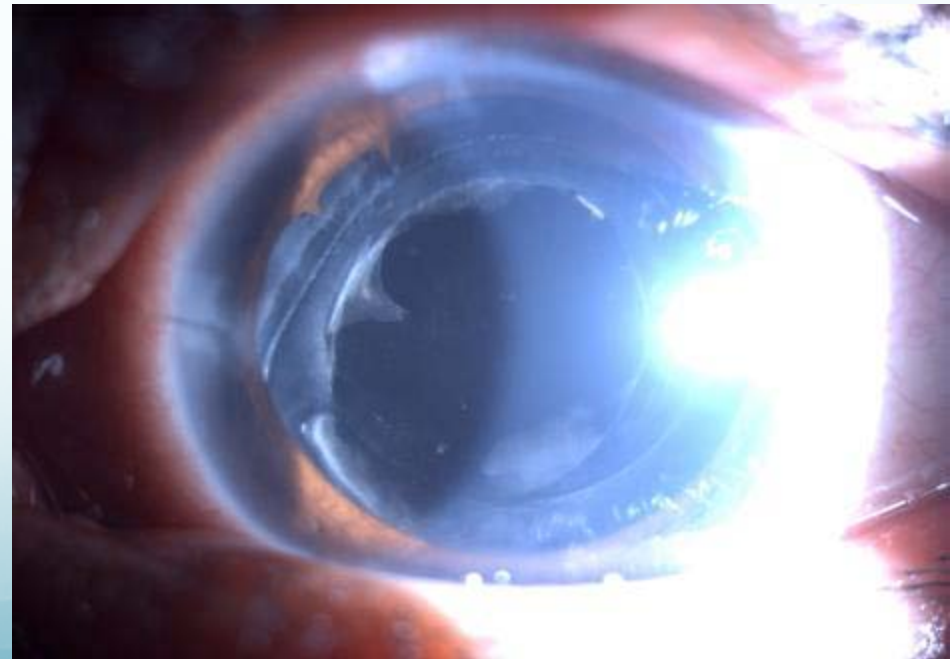
- S/p cataract surgery.
- VA; 6/12 Nv 6/6.
- Treatment: systemic and local immunosuppression which was tapered over six months.
- During this period patient presented with high IOP hence started on anti glaucoma medication

CURRENT

VN: 6/36

MEDICATION : topical steroid once daily ,topical antiglaucoma , and oral diamox.

No systemic immunosuppression .



CURRENT CHALLENGES :

PCO

GLAUCOMA : Persistent raised IOP
with increase in cup disc ratio

WHAT NEXT?

YAG...FOLLOWED BY TRAB?

TRAB...FOLLOWED BY YAG?

YAG...FOLLOWED BY ANY OTHER
OPTION FOR GLAUCOMA?

[Click here to answer above question](#)

