

CASE 4

Dr. Monica Samant
Laxmi Eye Institute
Mumbai (India)

- A 6yr old child was detected with poor vision in her left eye during school screening and referred to the base hospital for further management.
- Past history : Parents relate an episode which had occurred 6 months ago, wherein the child was hit by a stone in the left eye. They noticed redness in her left eye for which she was treated with topical drops given by local physician (no ophthalmic checkup).

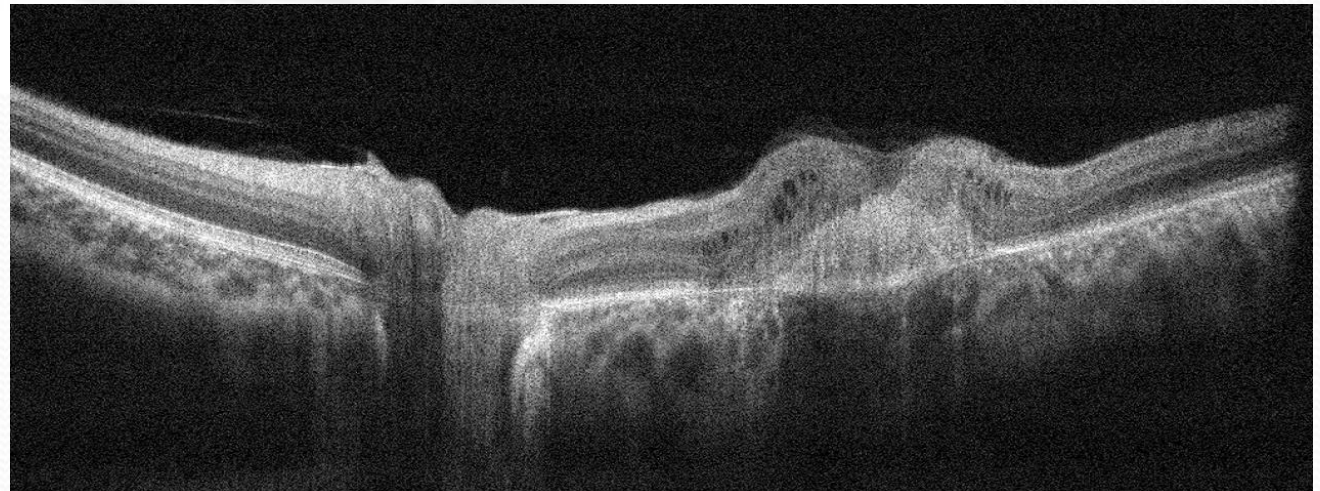
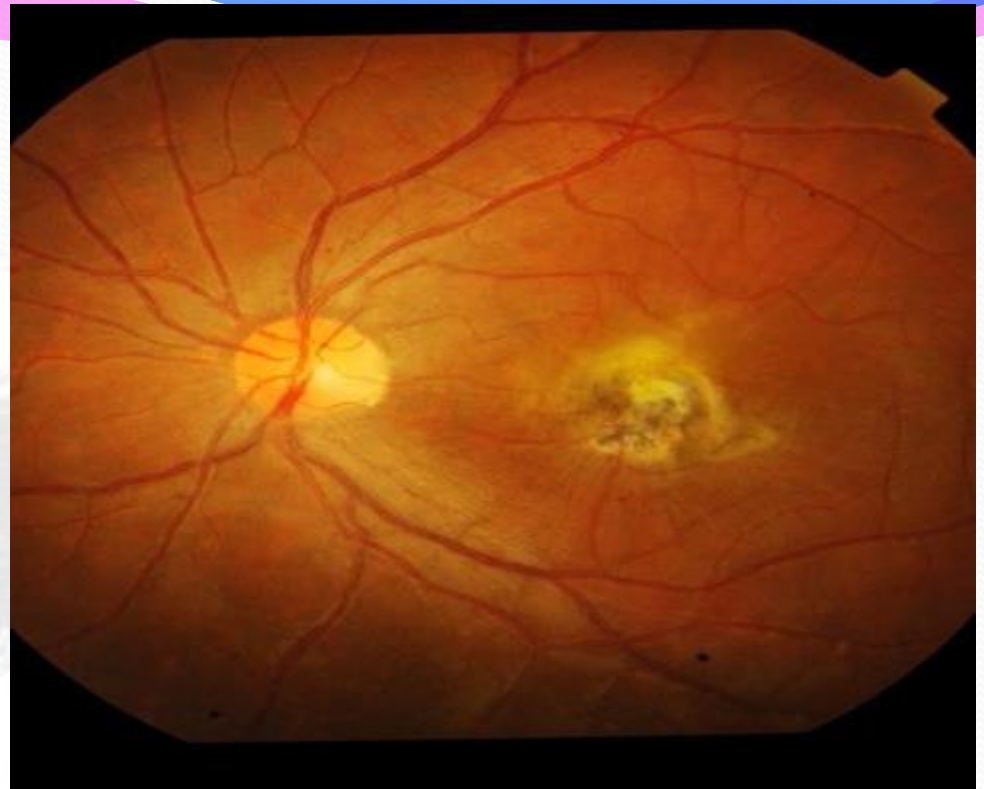
VN : (OD) 6/6 N6
(OS) 6/36 N36

NO IMPROVEMENT WITH
GLASSES

REST ANT SEGMENT : WNL

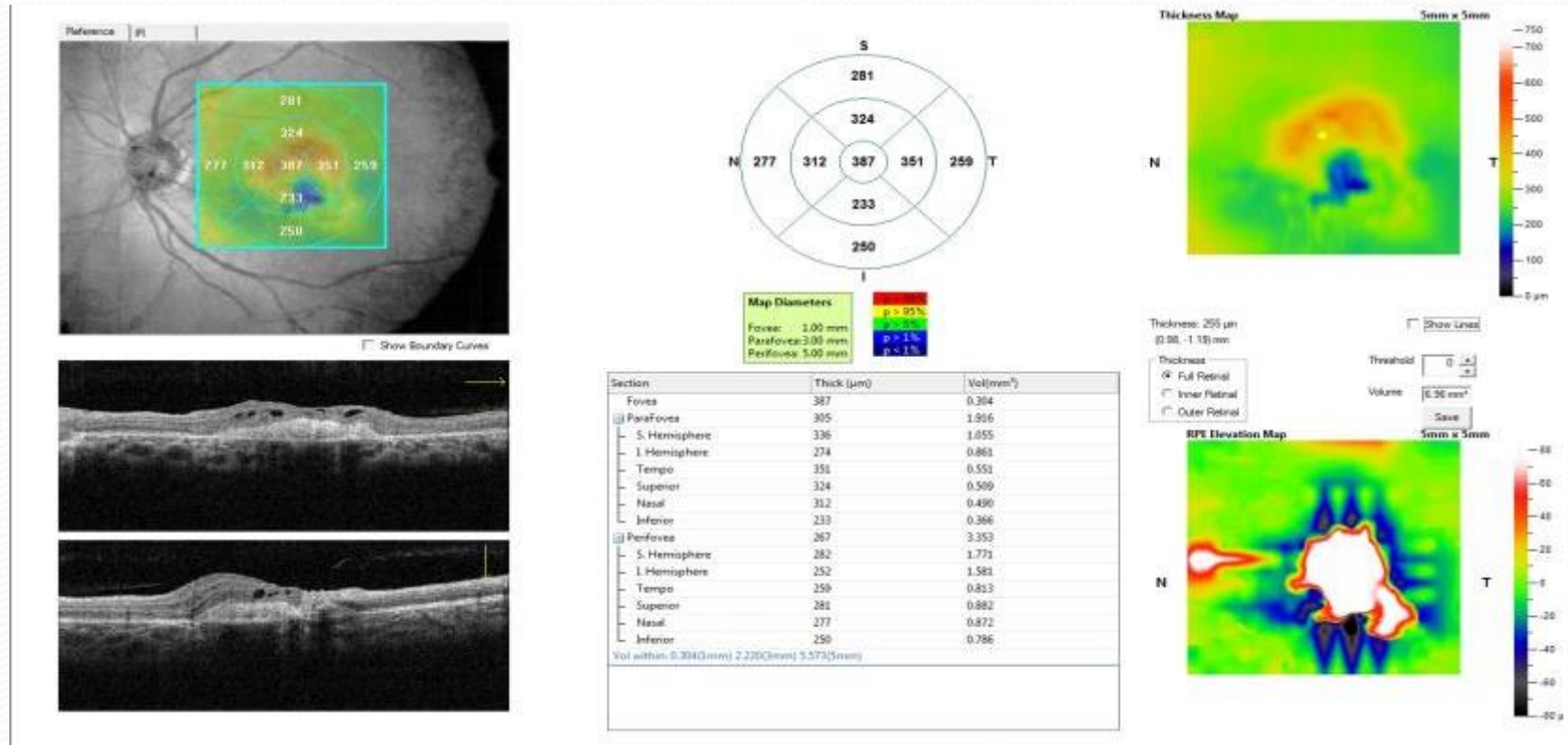
RETINA : (OD) WNL
(OS) CNVM

DIAGNOSIS :
TRAUMATIC CNVM

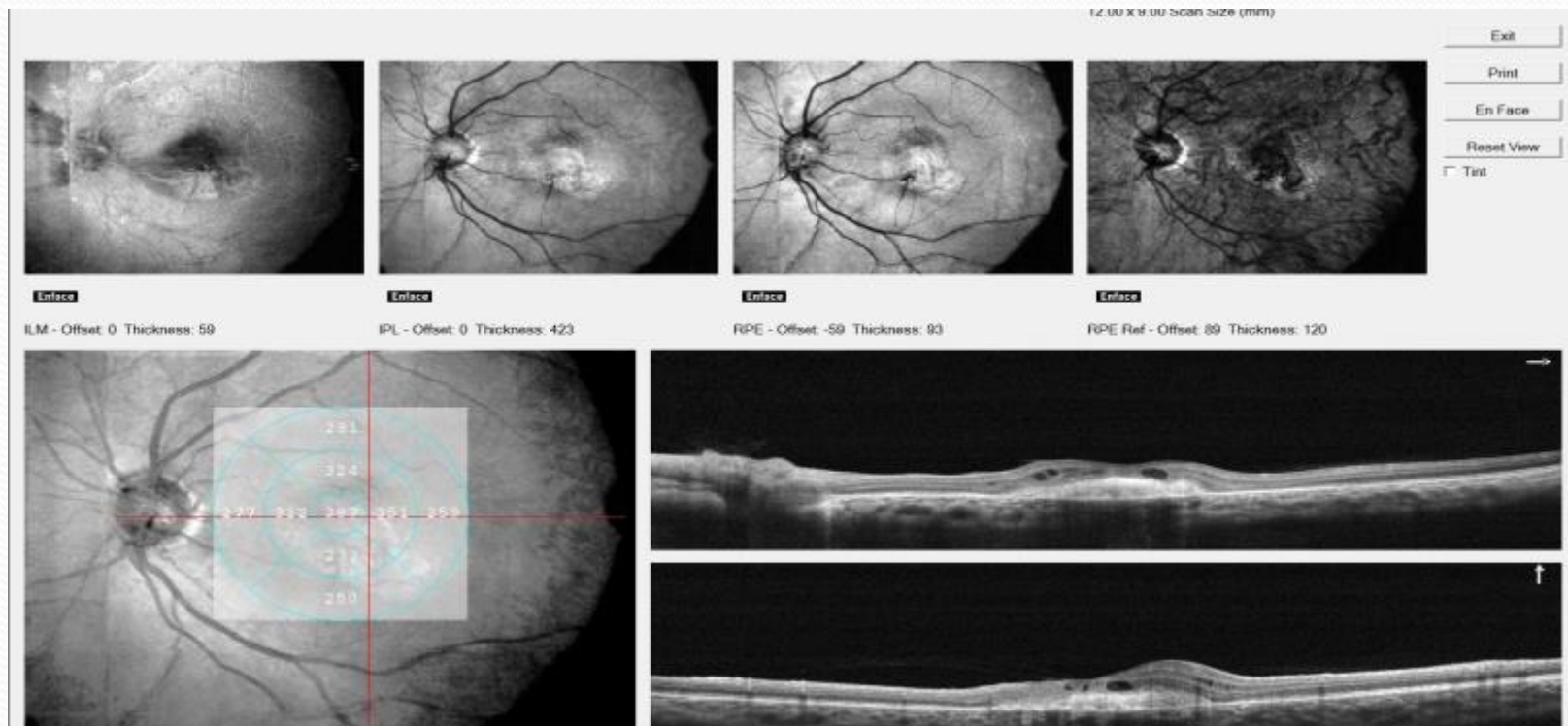


Retina map

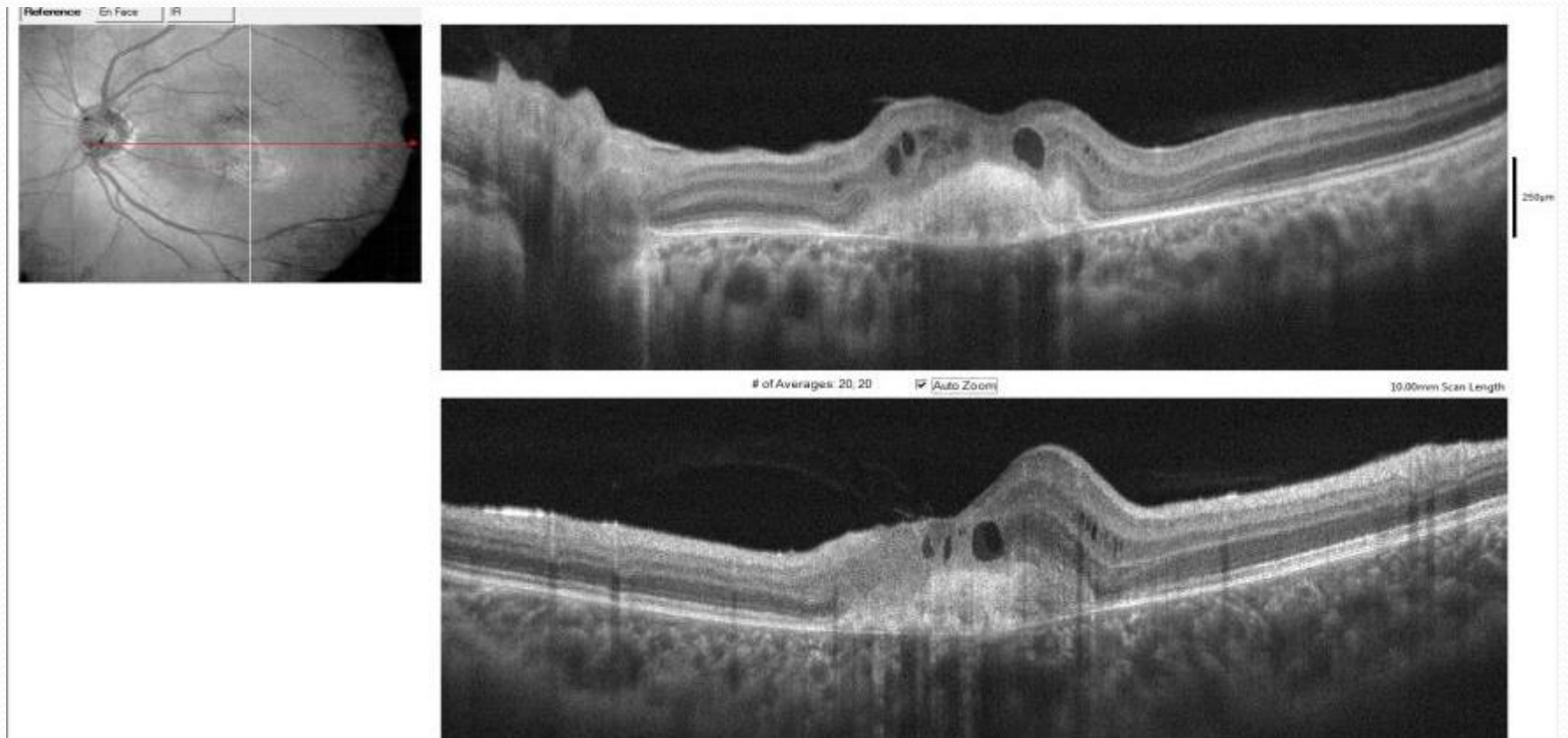
Left/OS



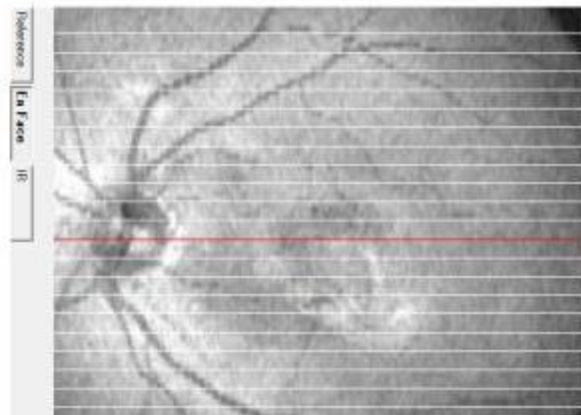
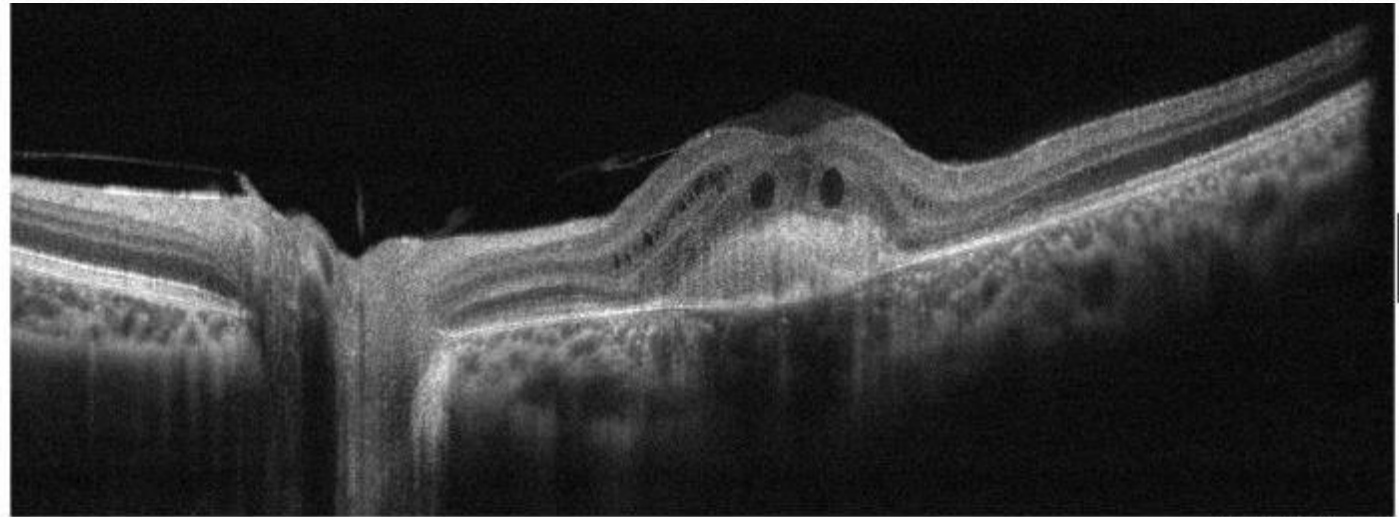
Left/OS



Left/OS



Left/OS



HOW WOULD YOU TREAT THE CONDITION?

1. Would you Leave the Condition Untreated / As it is?
2. Would you Use Anti-VEGF ?
3. Would you Perform Surgery?
4. Would you Administer an Intravitreal Steroid?



Thank you !!