

# CASE 4

Dr. Monica Samant  
Laxmi Eye Institute  
Mumbai (India)

- A 6yr old child was detected with poor vision in her left eye during school screening and referred to the base hospital for further management.
- Past history : Parents relate an episode which had occurred 6 months ago, wherein the child was hit by a stone in the left eye. They noticed redness in her left eye for which she was treated with topical drops given by local physician (no ophthalmic checkup).

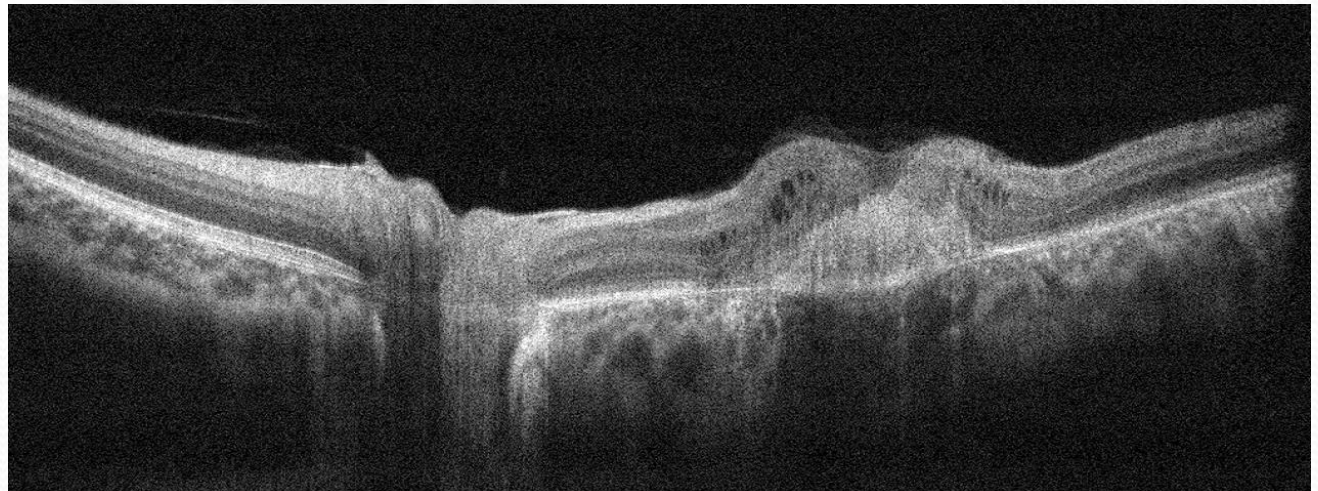
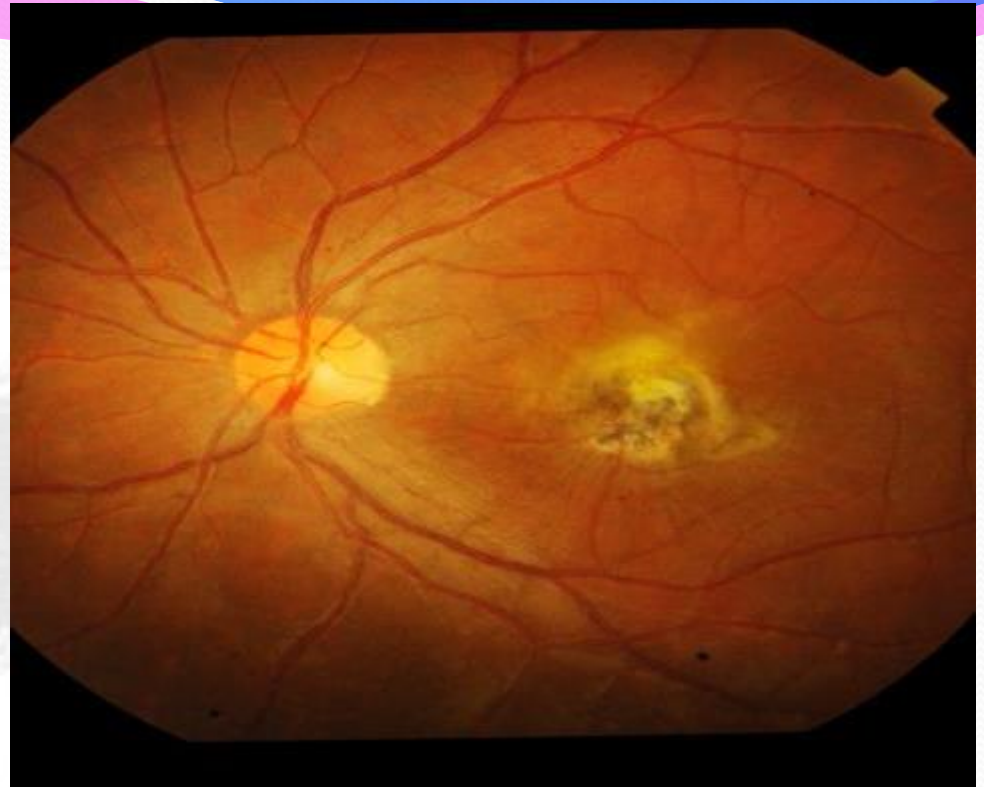VN : ( OD) 6/6 N6  
(OS) 6/36 N36

NO IMPROVEMENT WITH  
GLASSES

REST ANT SEGMENT : WNL

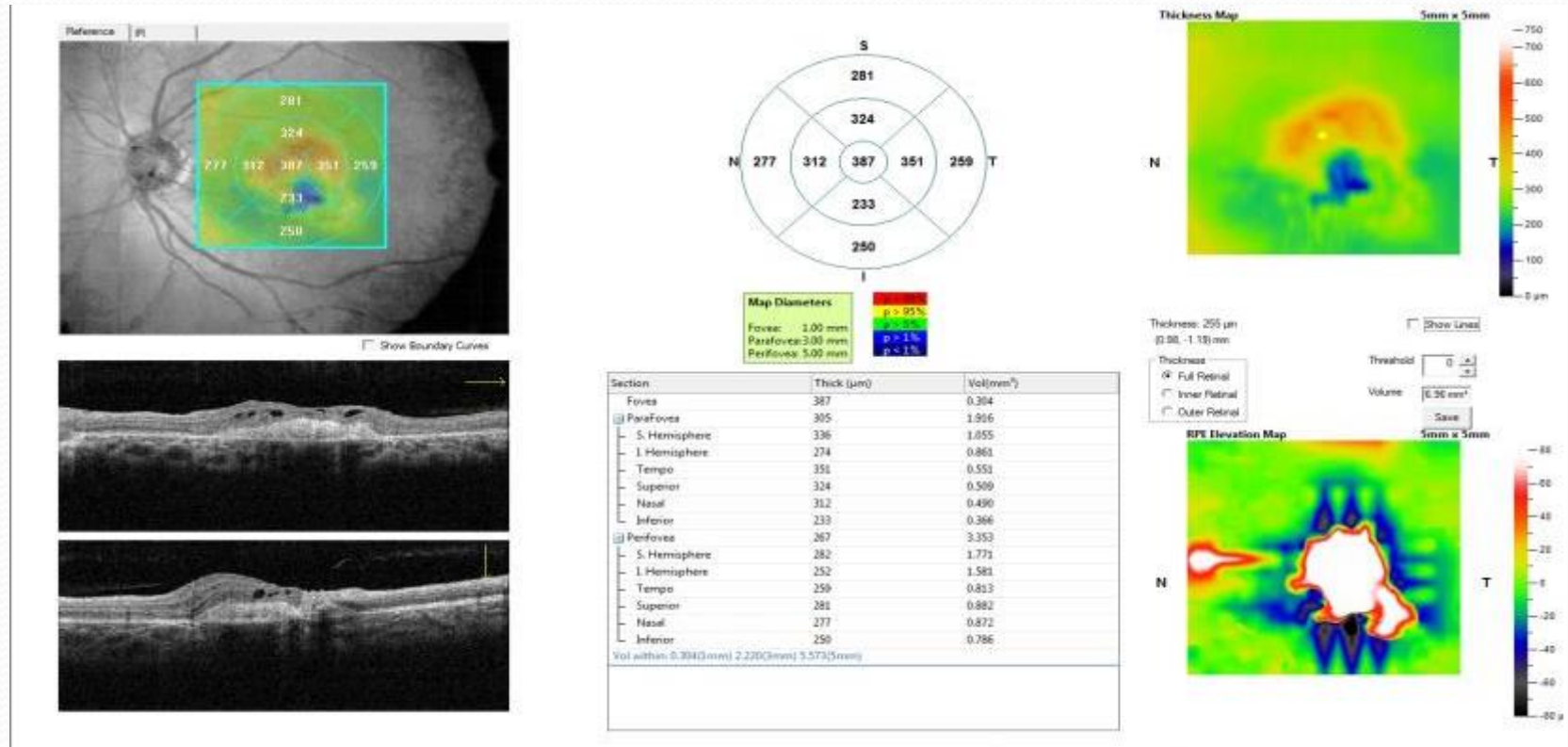
RETINA : (OD) WNL  
(OS) CNVM

DIAGNOSIS :  
TRAUMATIC CNVM

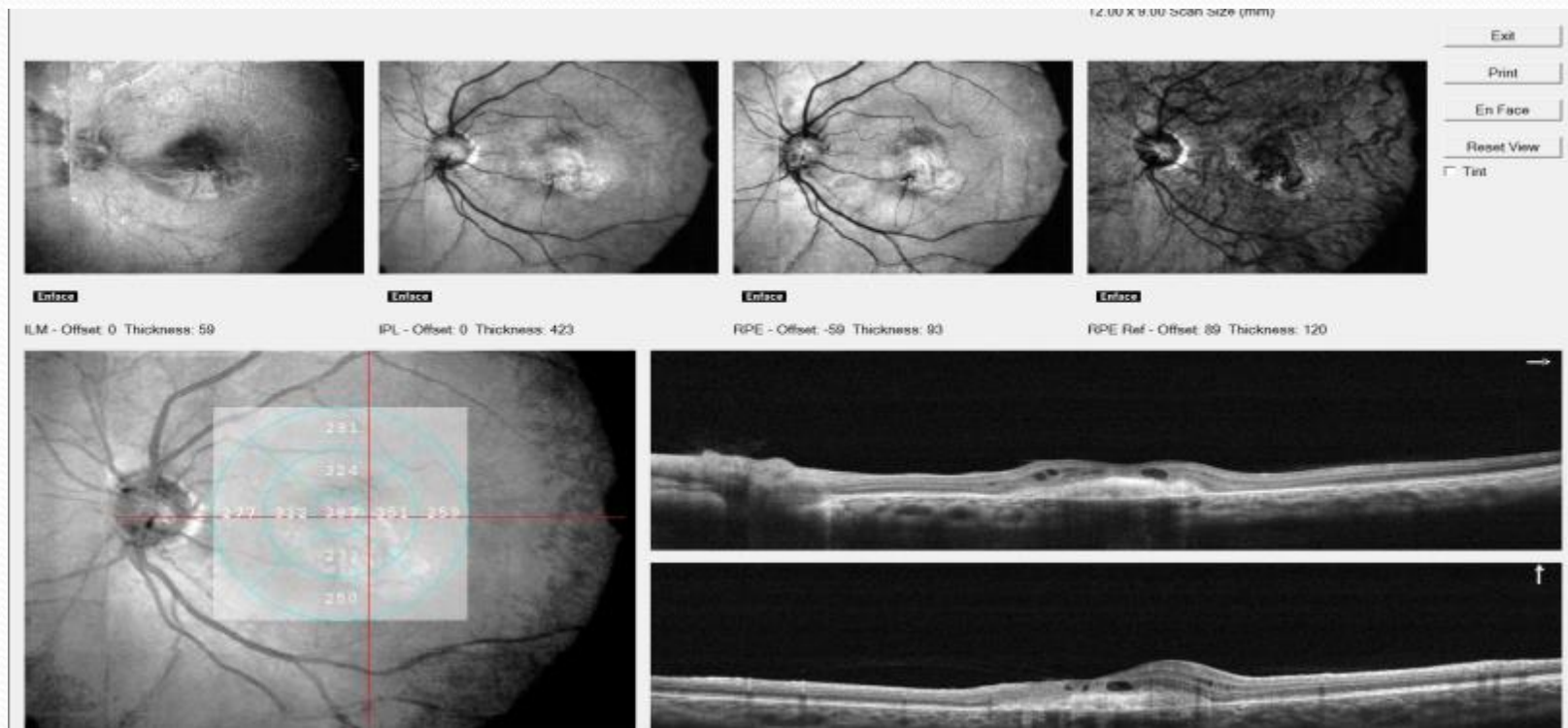

# Retina map

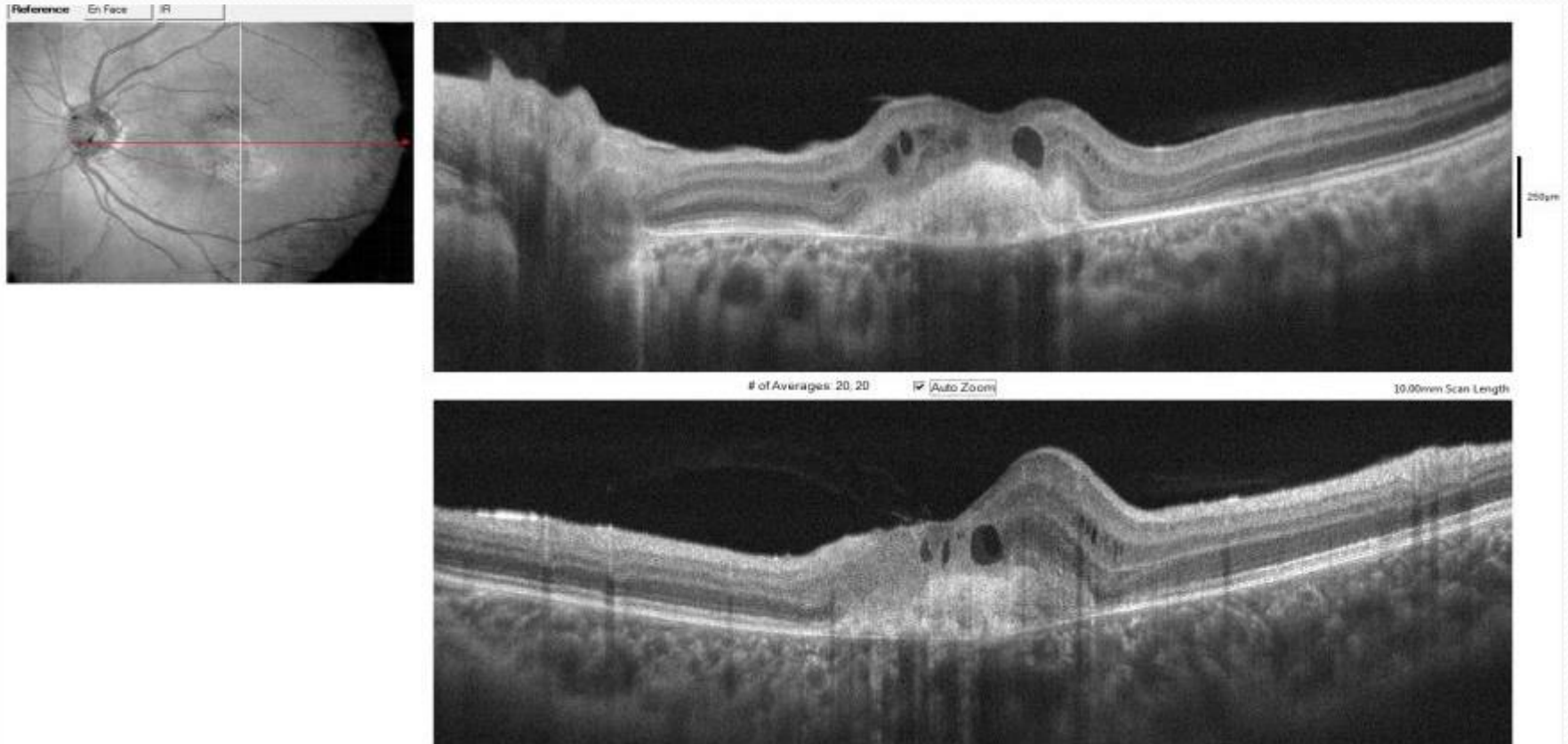
# Left/OS



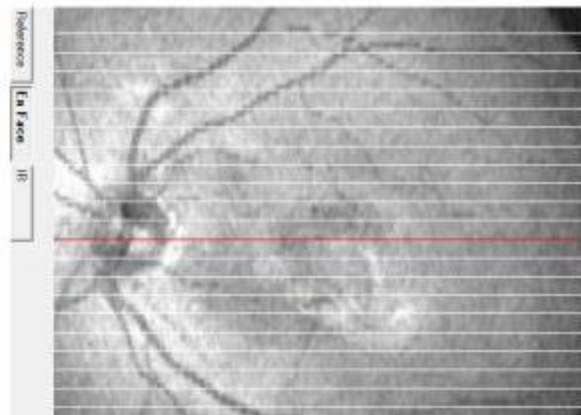
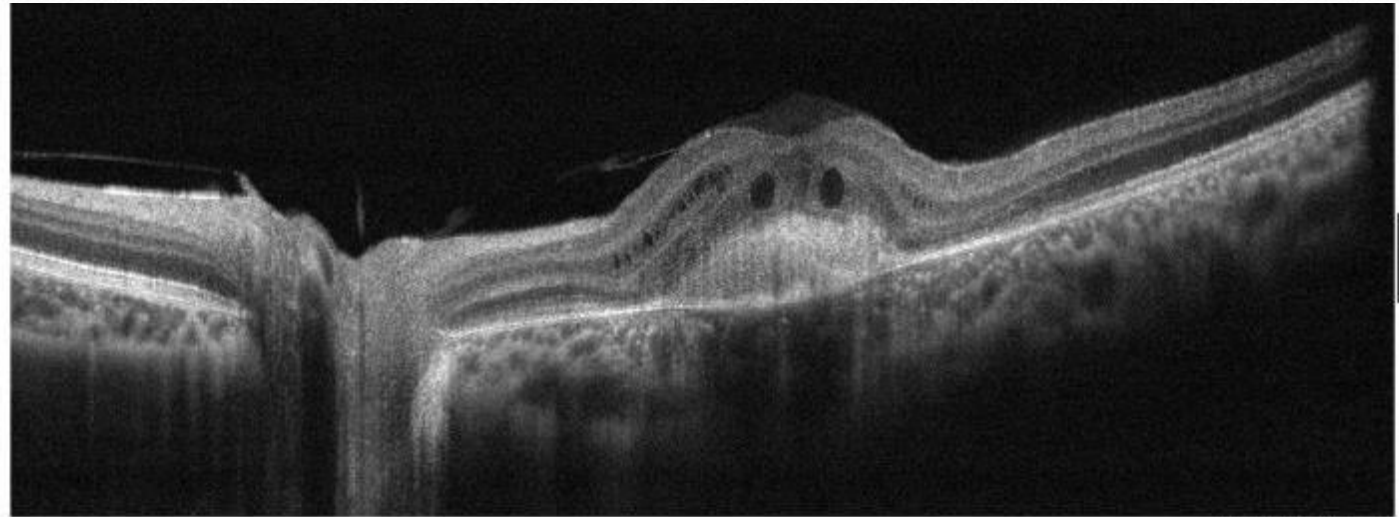
# Left/OS



# Left/OS



# Left/OS



# HOW WOULD YOU TREAT THE CONDITION?

1. Would you Leave the Condition Untreated / As it is?
2. Would you Use Anti-VEGF ?
3. Would you Perform Surgery?
4. Would you Administer an Intravitreal Steroid?





Thank you !!