

3RD JOINT CASE REPORT



REVISTA DE
ESTRABISMO
& OFTALMOLOGIA PEDIATRICA

ISSN: 2362-3764

AND



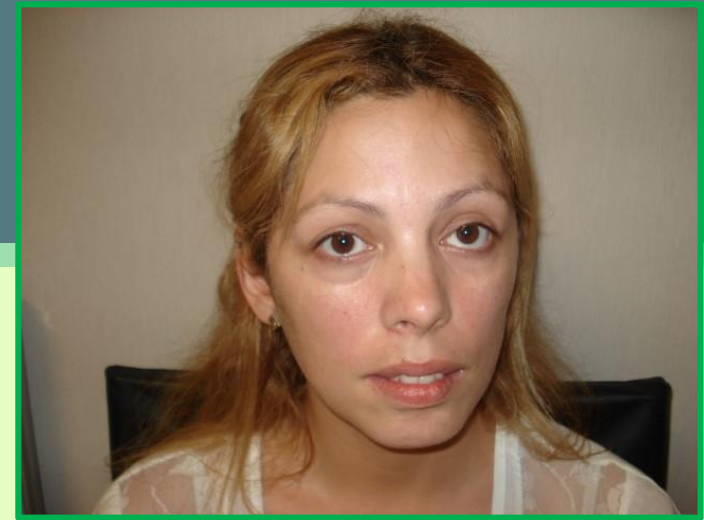WSPOS

World Society of Paediatric
Ophthalmology and Strabismus



SUSANA GAMIO, MD
Buenos Aires, ARGENTINA

Case :



- 32 yo lady
Anomalous Head Posture: Left Head Turn
Visual Acuity: OD 1.0 OS 0.7
OD 0.25 x 78 OS 0.25 -1.50 x 168
A pattern XT. Bilateral SOOA. NRC.
- Right limitation of elevation in adduction
- Lang (+) in rightgaze. Normal MRI.
- Cover test:

4 XT 4 LHT

10 XT 4 LHT

8 XT 20 LHT

6 XT 8 LHT

12 XT 18 LHT

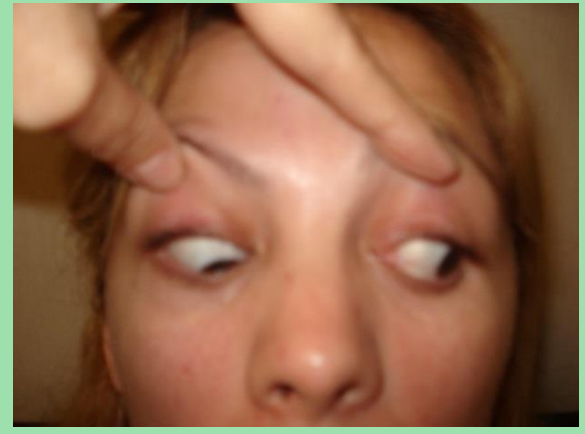
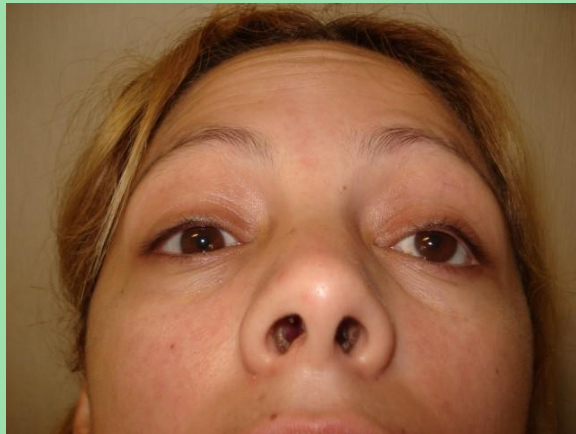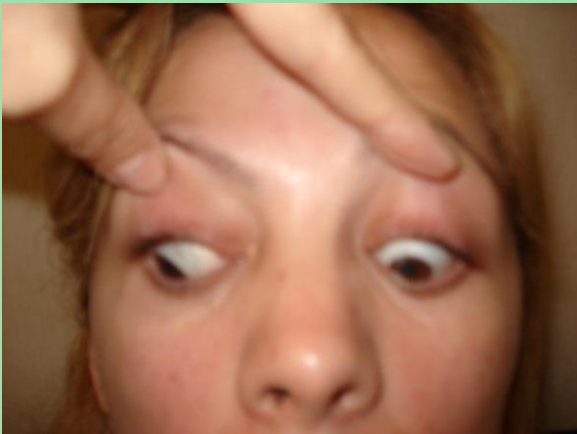
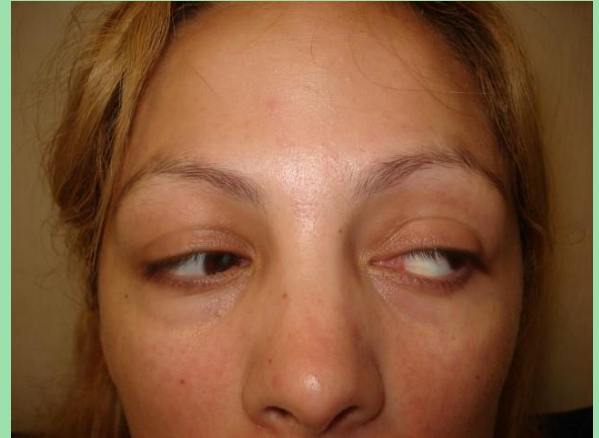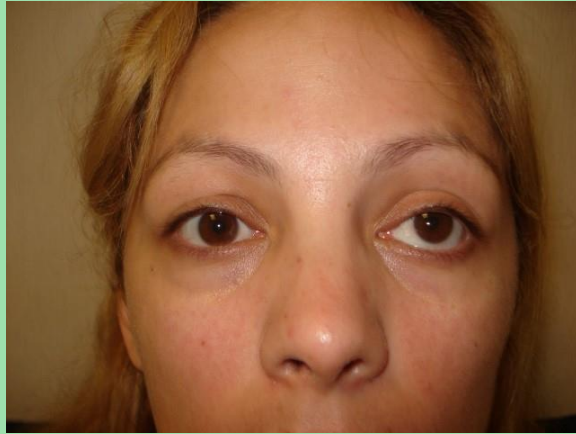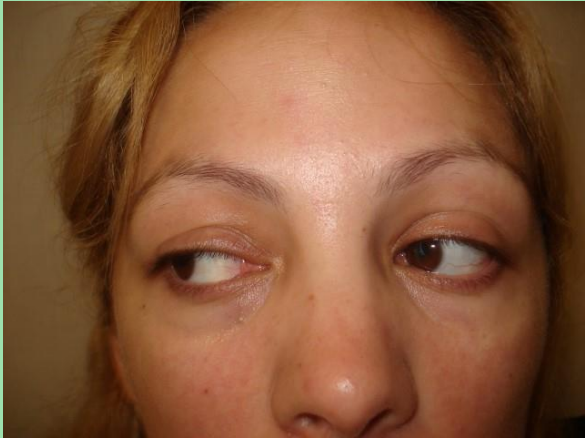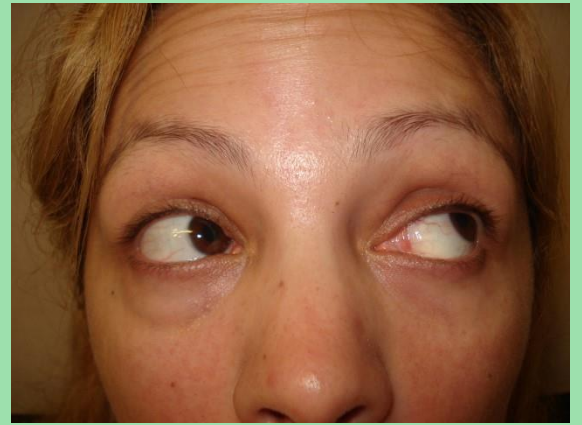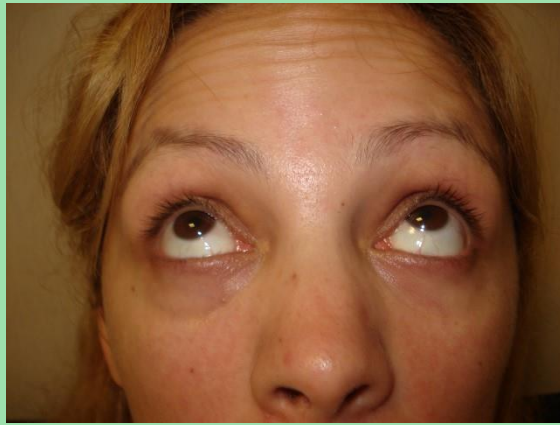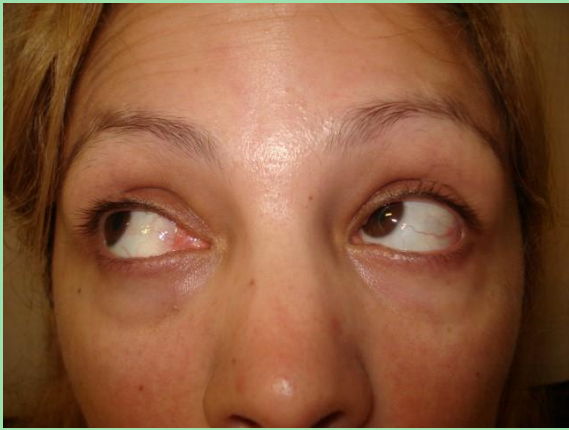15 XT 25 LHT

20 XT 15 LHT

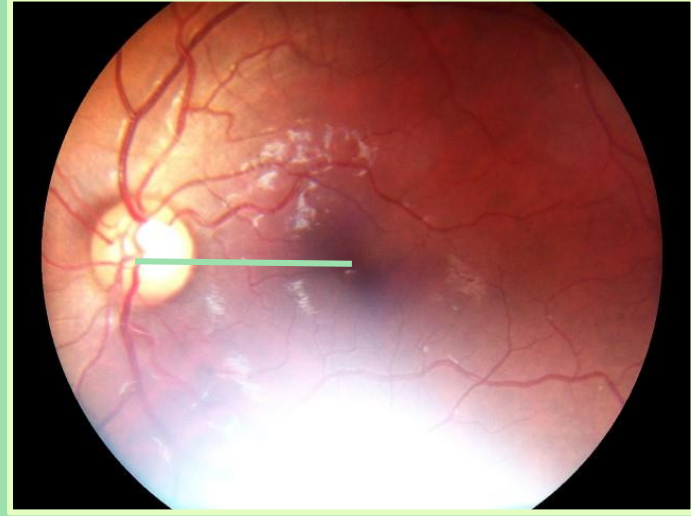
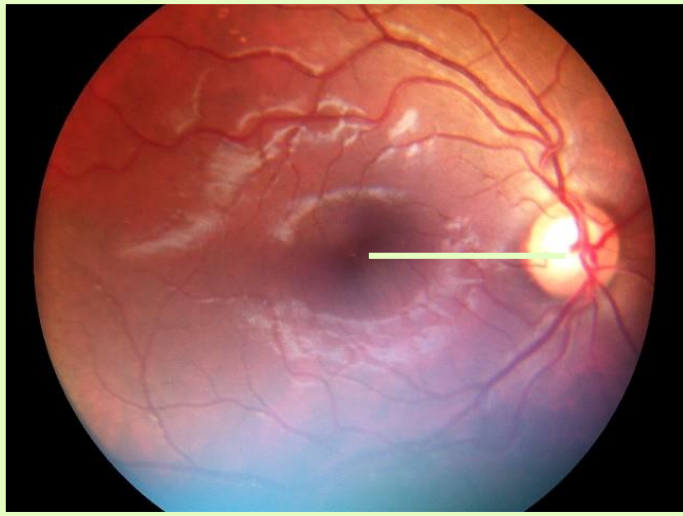
25 XT 16 LHT

20 XT 30 LHT

Bielschowsky RHT 20XT 12 LHT LHT 12 XT 20 LHT



Objective Torsion



- Bilateral intorsion > in OD

VOG 3D: Both Eyes Without Occlusion

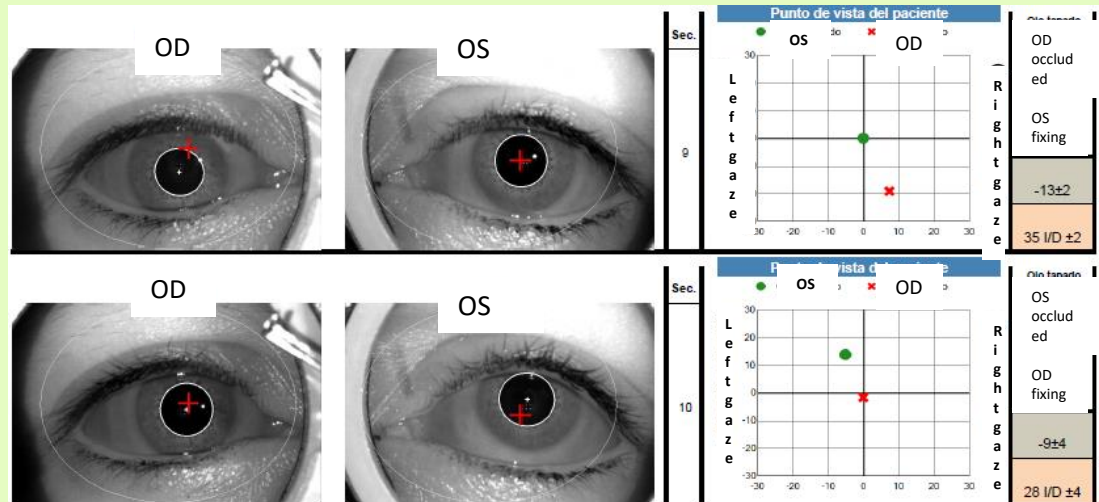
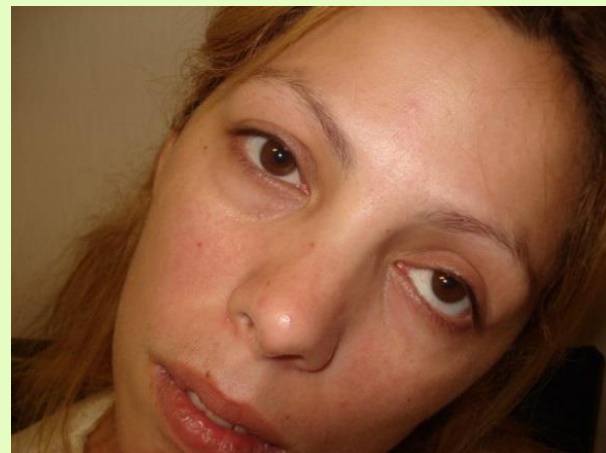
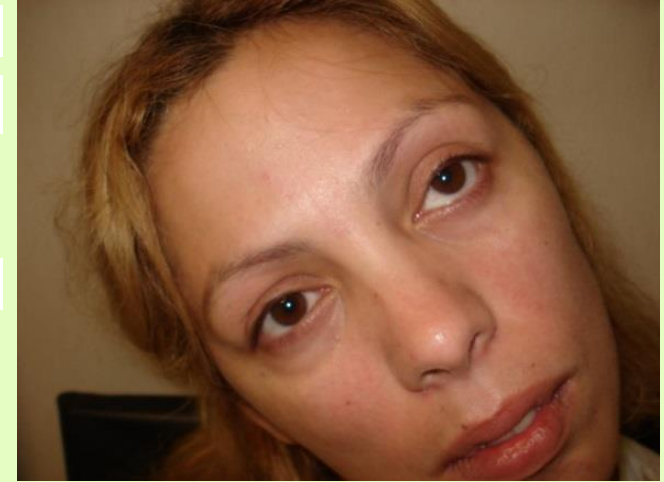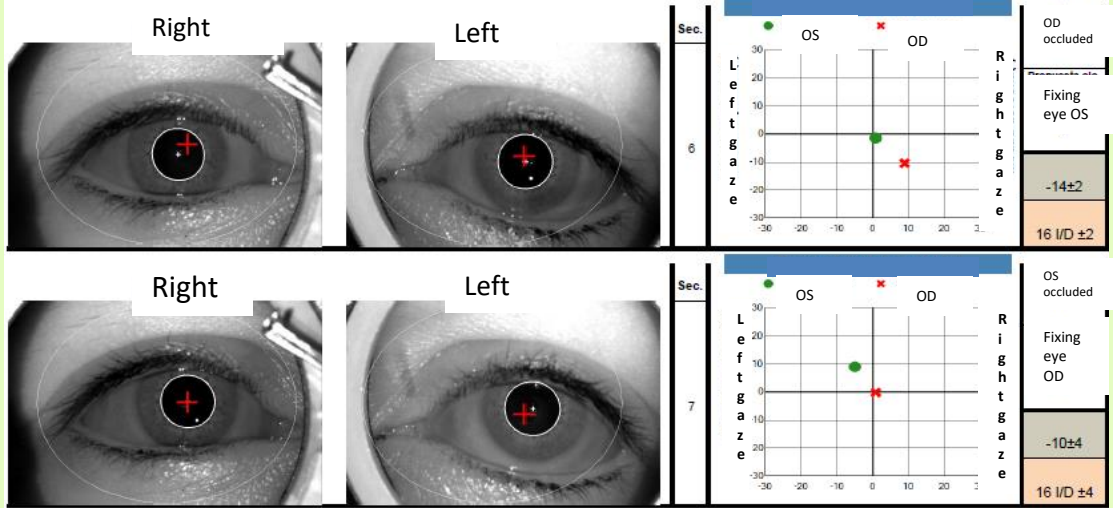
PP: 10 XT 24 LHT

R
i
g
h
t
g
a
z
e

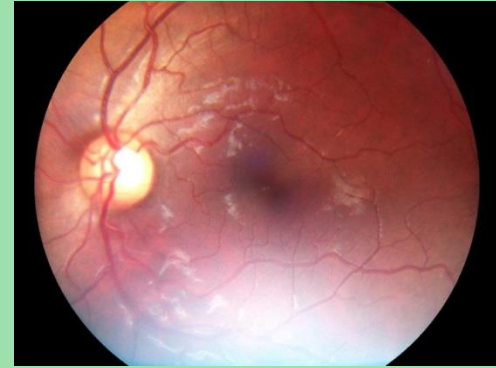
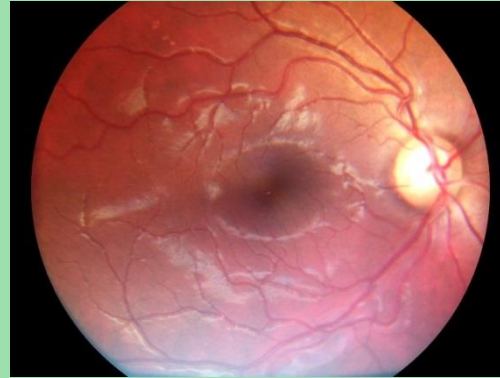
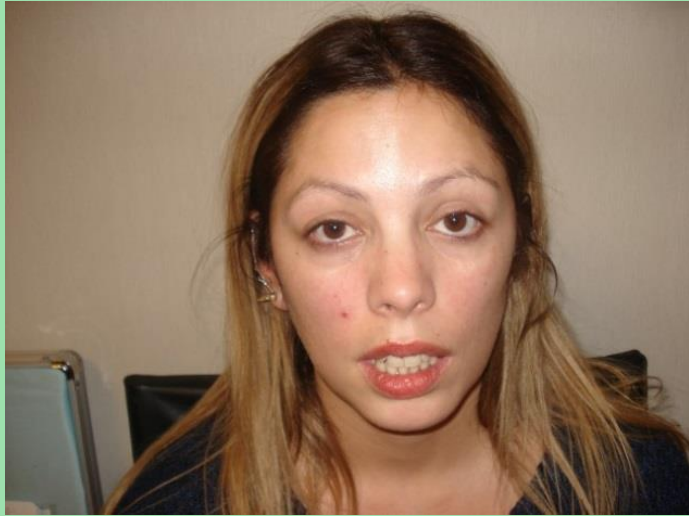L
e
f
t
g
a
z
e

	17°						17°
-17°	Both eyes		Both eyes		OD		17°
	+2±5	1 I/D ±5	-2±5	6 I/D ±5	-7±6	18 I/D ±6	
	-	0±1	-	1 2±1	0±1	E 2±1	
	Both eyes		OD		OD		
	-1±4	0±4	-10±3	24 I/D ±4	-10±6	24 I/D ±6	
	E 5±2	1 1±1	-	1 1±1	0±1	0±1	
	OD		OD		OD		
-17°	-9±5	17 I/D ±5	-13±4	28 I/D ±4	-12±5	34 I/D ±5	17°
	1 1±1	1 4±1	0±1	1 3±1	1 1±1	-	
	-17°						-17°

Head Tilt Test



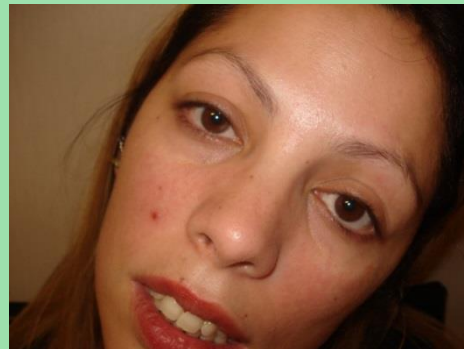

Post-op

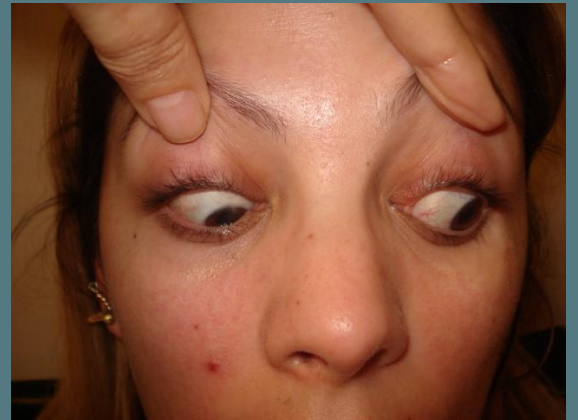
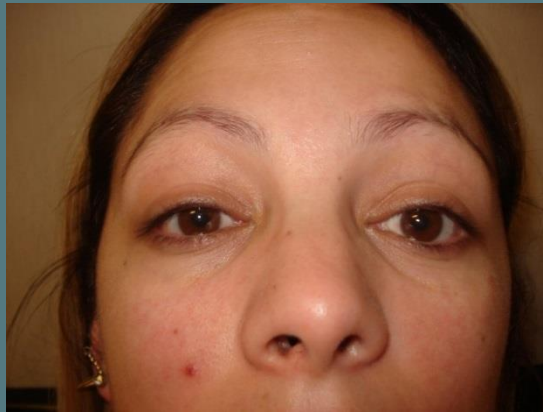
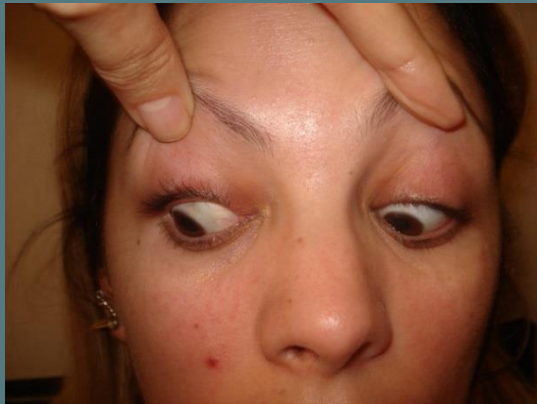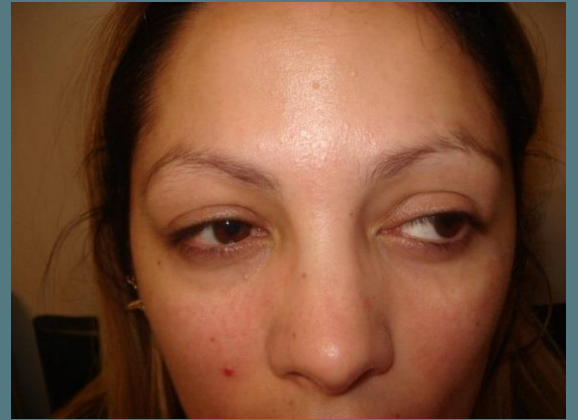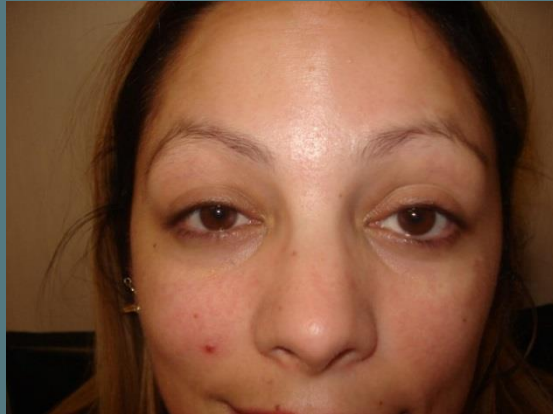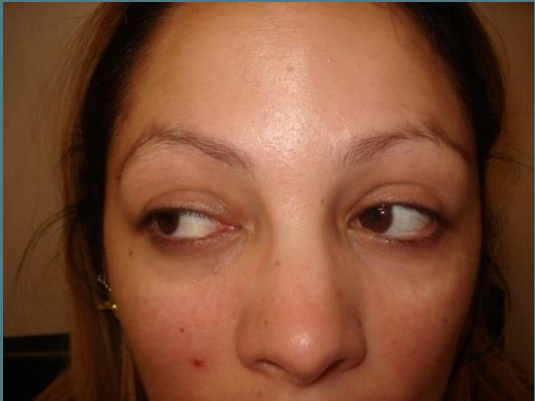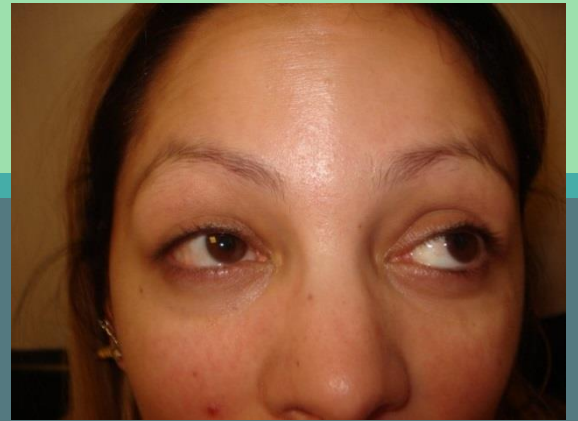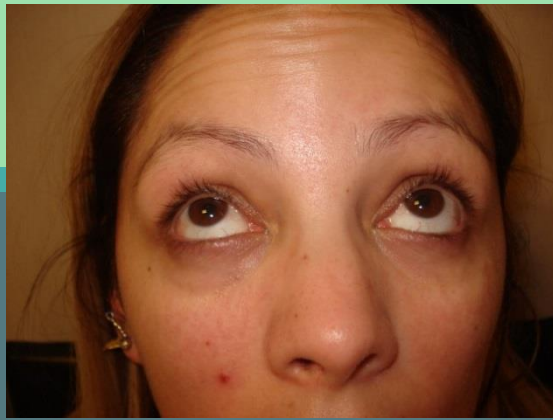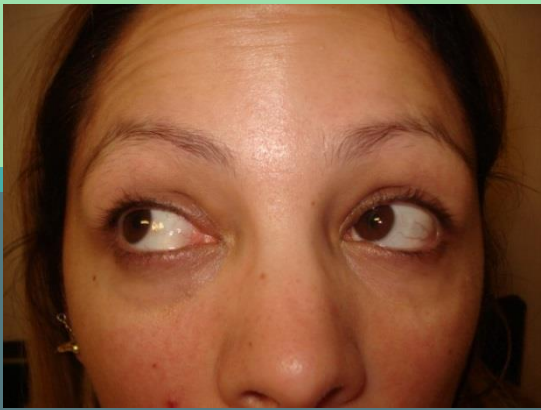Surgery :

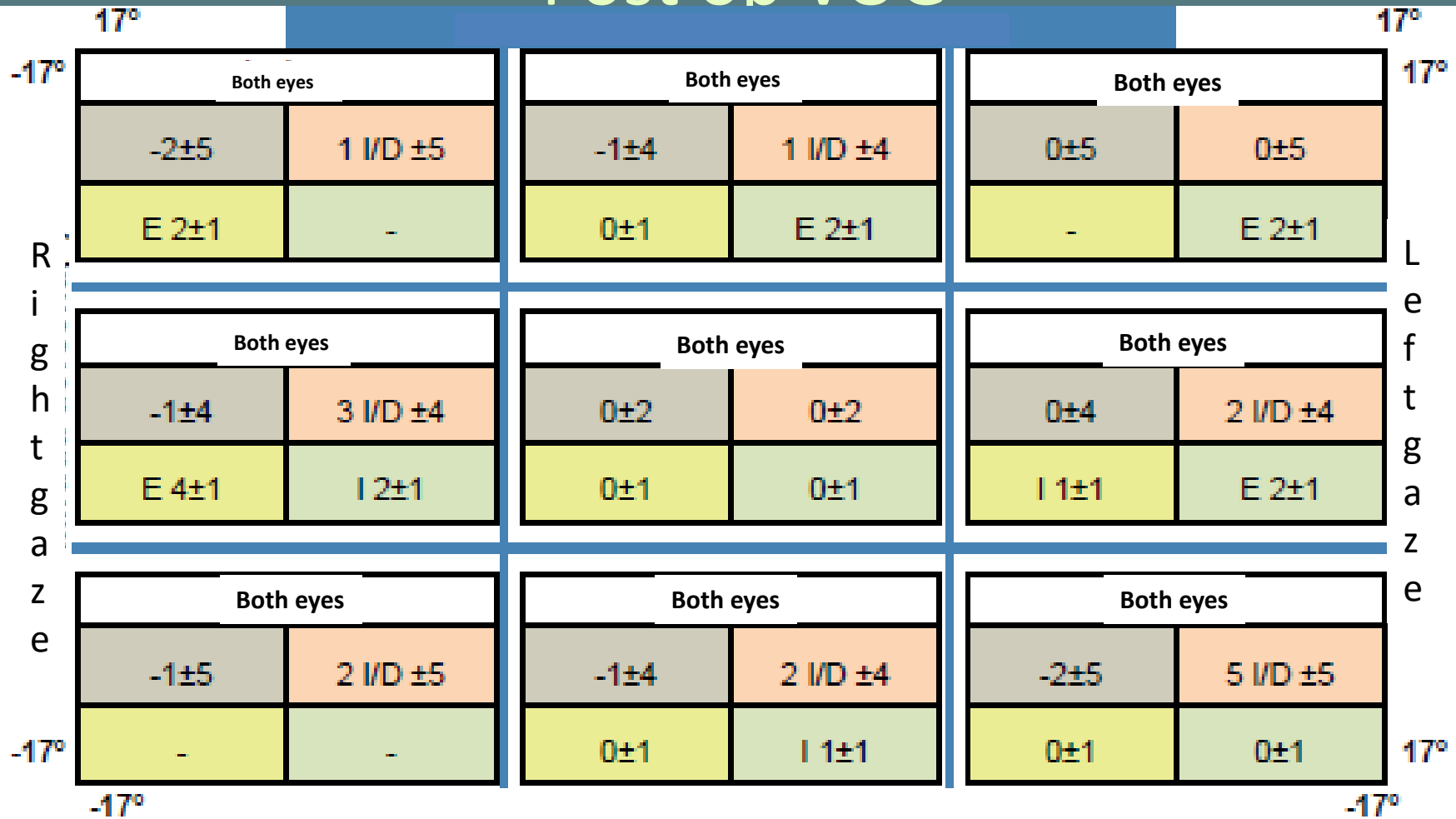
Negative Forced Duction

OD 5 mm RLR recession RSO posterior
tenectomy OS 5 mm LSR recession



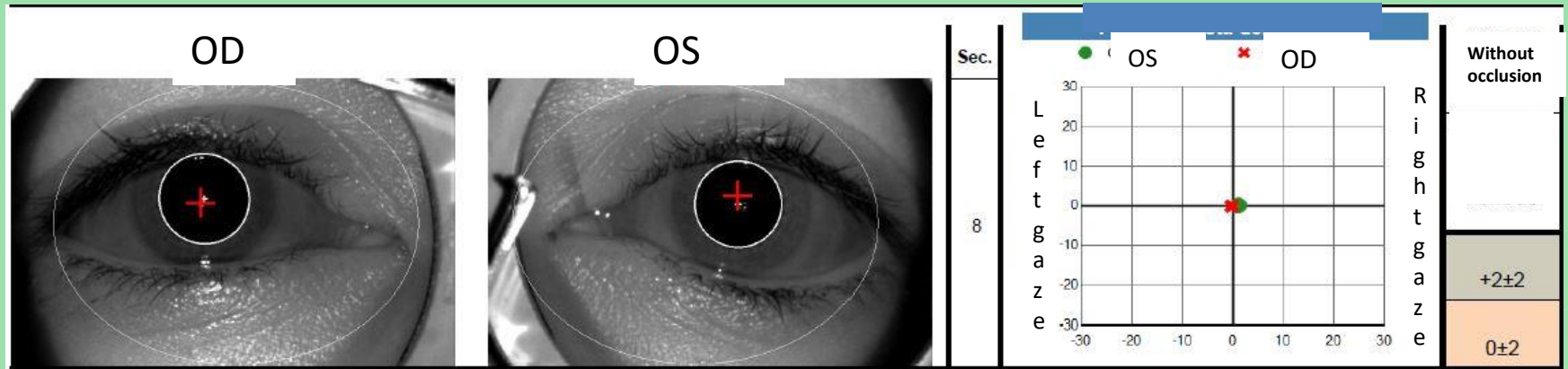


Post op VOG

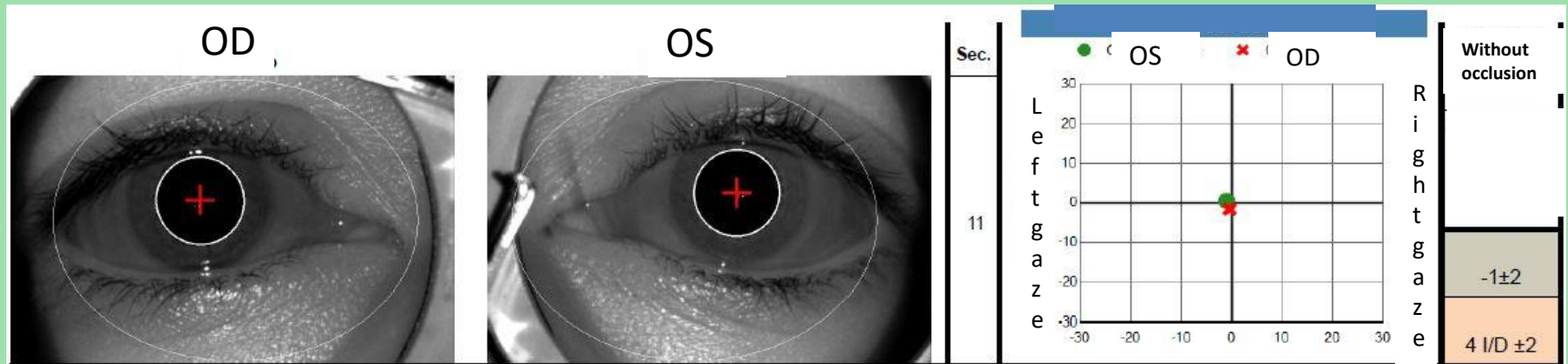


Post op Head Tilt Test

Post op Right Head Tilt



Post op Left Head Tilt



❖ How do you explain this pattern?

A: III nerve paresis

B: IO palsy

C: A pattern XT with asymmetric SOOA ?

❖ Which procedure do you prefer for weakening SOOA?

A: SO tenectomy

B: SO tendon elongation

C: SO tendon recession

❖ How do you explain the Head Tilt Test difference?

A: IO palsy

B: SR overaction/contracture syndrome

C: XT with asymmetric SOOA

COULD OUR EXPERTS PLEASE ANSWER THE FOLLOWING QUESTIONS IN ADDITION TO ANSWERING THE QUESTIONS ON THE PREVIOUS SLIDE?

- Do you think that IO palsy is a benign entity ?
- What is your approach to treat a patient with IO palsy pattern?

A dark teal circle is centered on a teal background. The text "Thank you!" is written in a light yellow-green color across the middle of the circle.

Thank you!