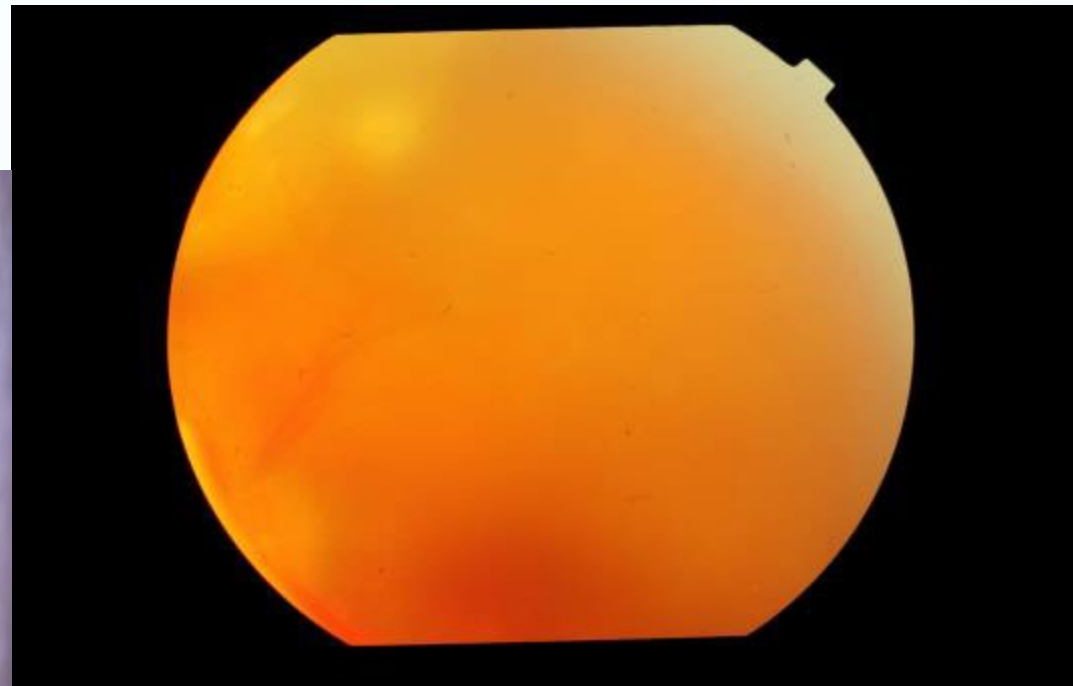
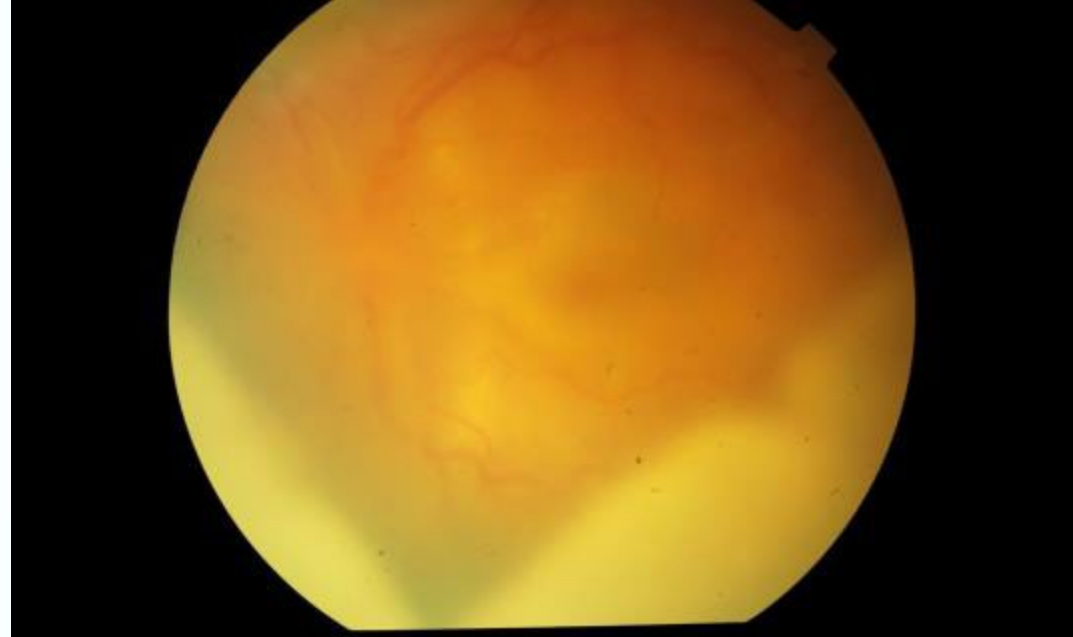


CASE 1

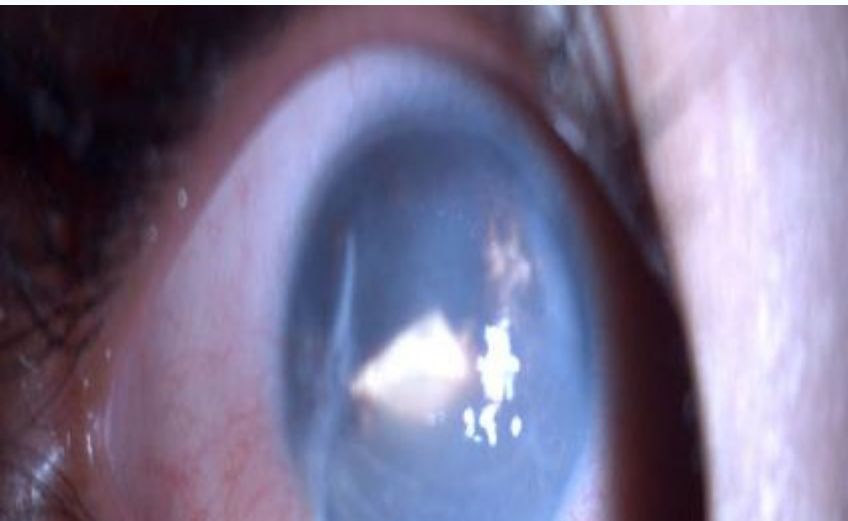DR MONICA SAMANT
LAXMI EYE INSTITUTE
MUMBAI (INDIA)

3 yr old female presented
with decreased vision in
left eye.

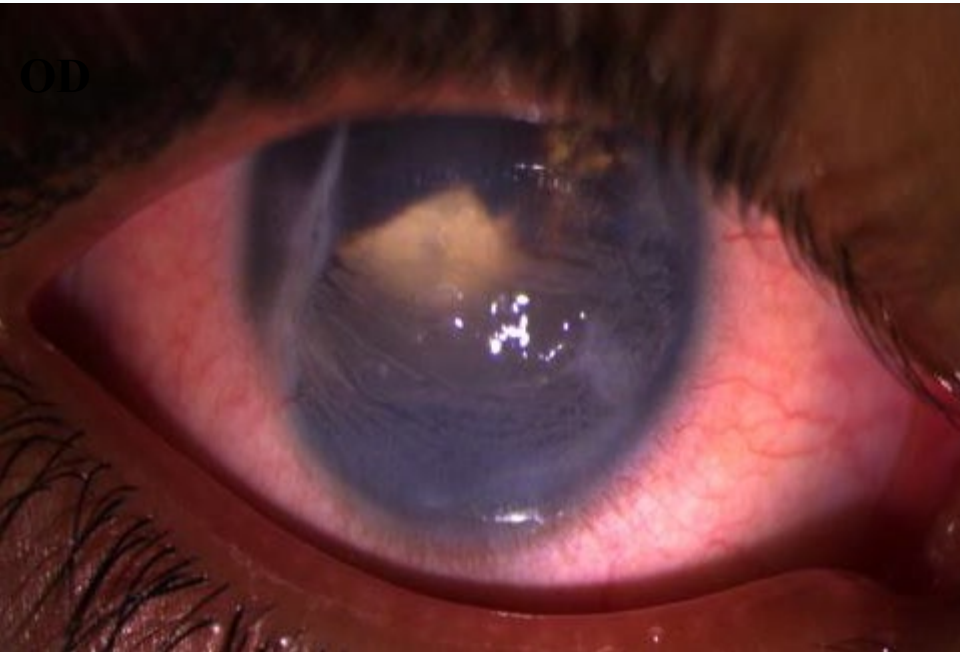
OD s/p repair for
penetrating trauma one
month ago elsewhere.



OD



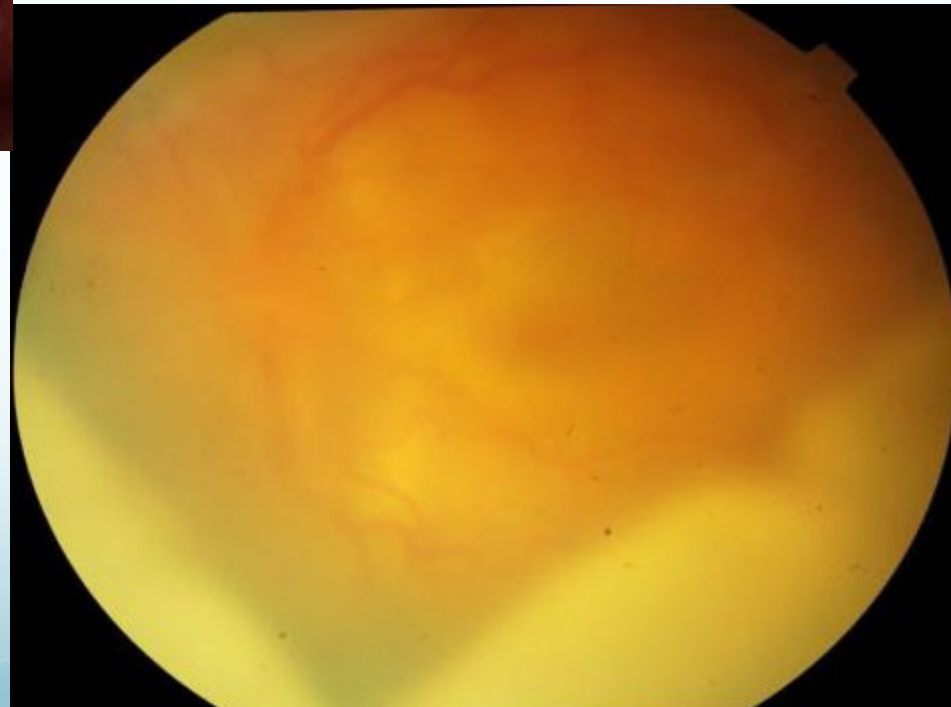
ON EXAMINATION - RE
Vn - PL



ON EXAMINATION - LE
Vn - CF – Close to Face
AC – Thick Membrane in AC
Posterior Segment – Hazy media

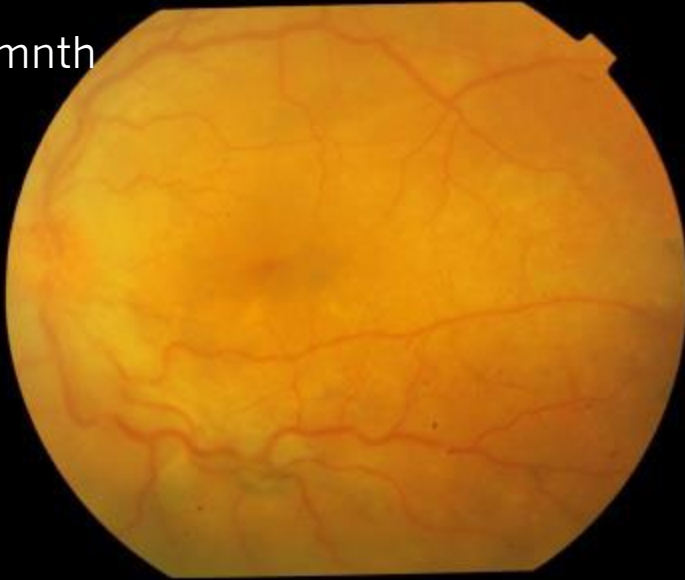B – Scan – LE – choroidal thickening

LE – Sympathetic Ophthalmia

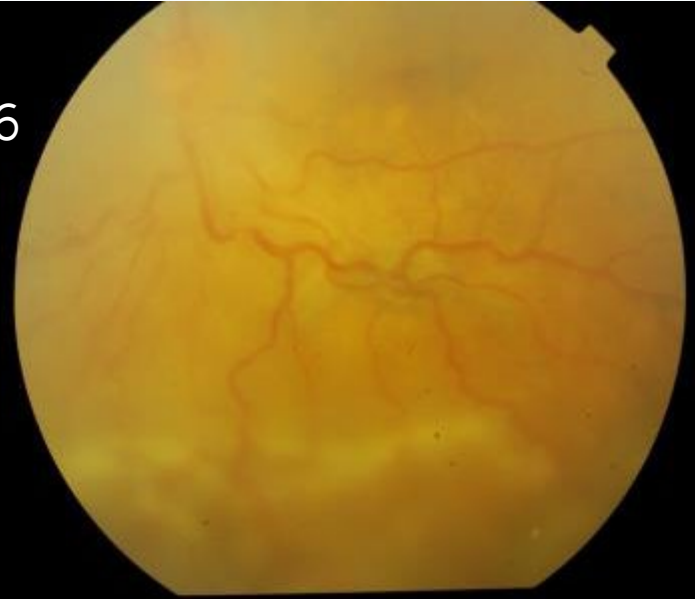

Treatment : systemic and local
immunosuppression

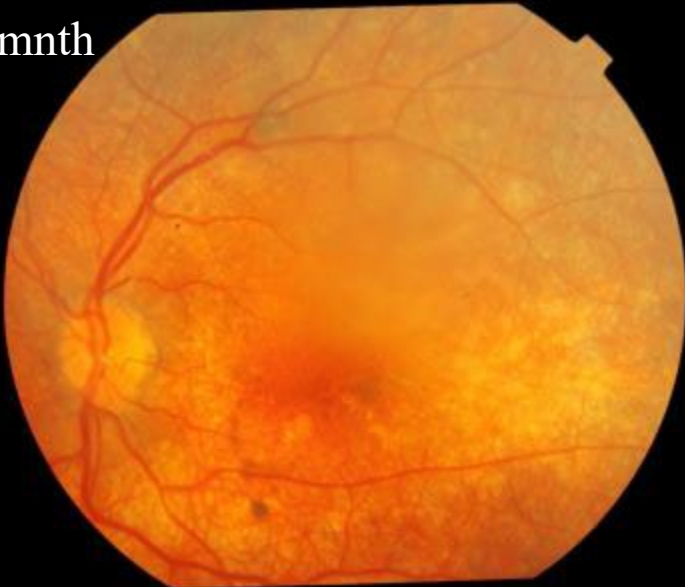At 1mnth



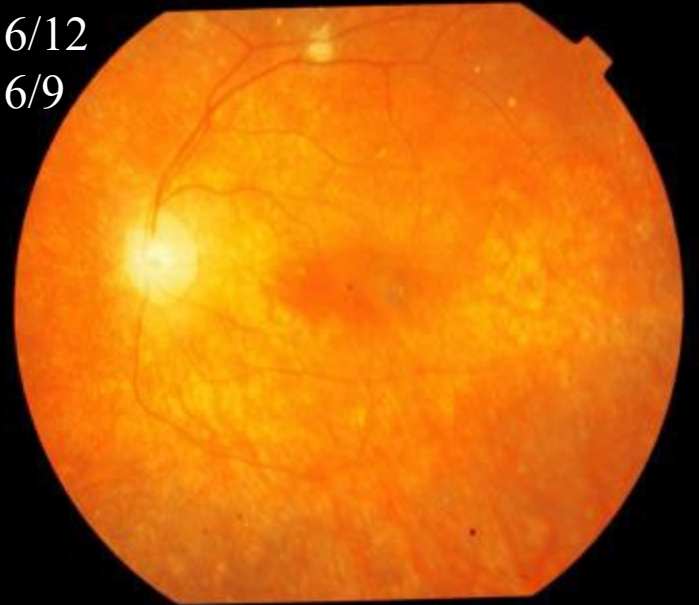
Vn
6/36



At 6mnth

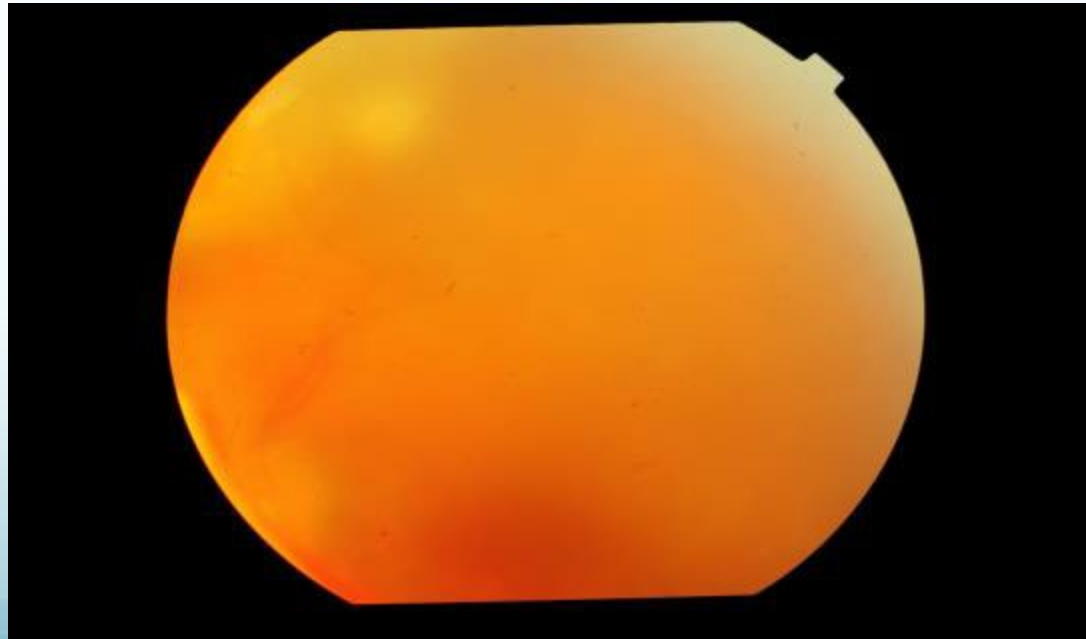
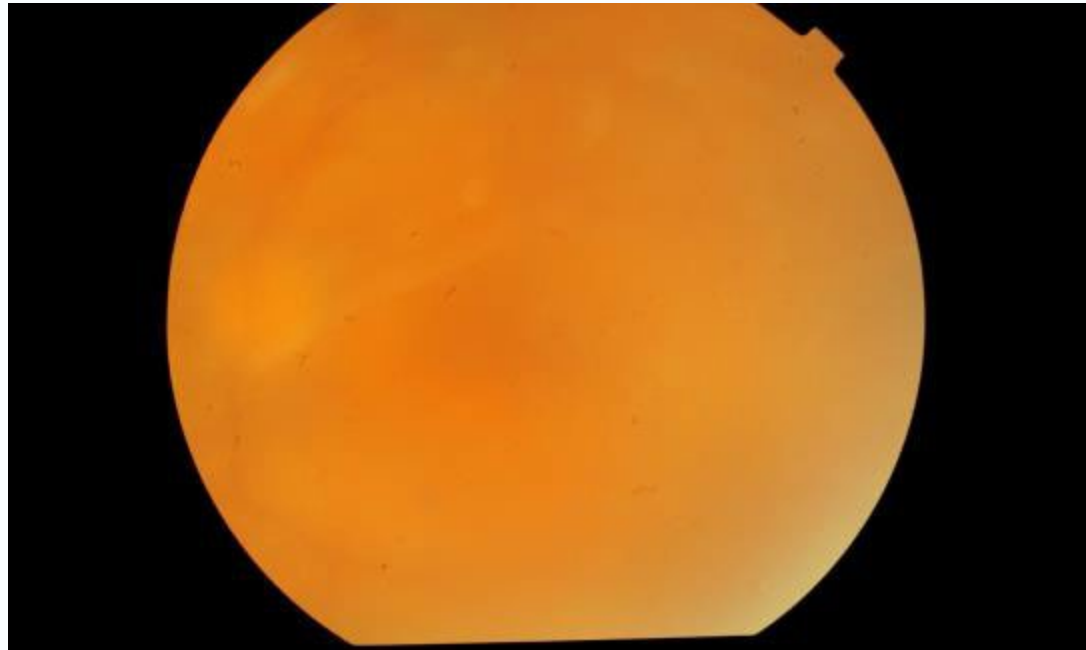


Vn 6/12
Nv 6/9



Lost to follow up came after
six months.

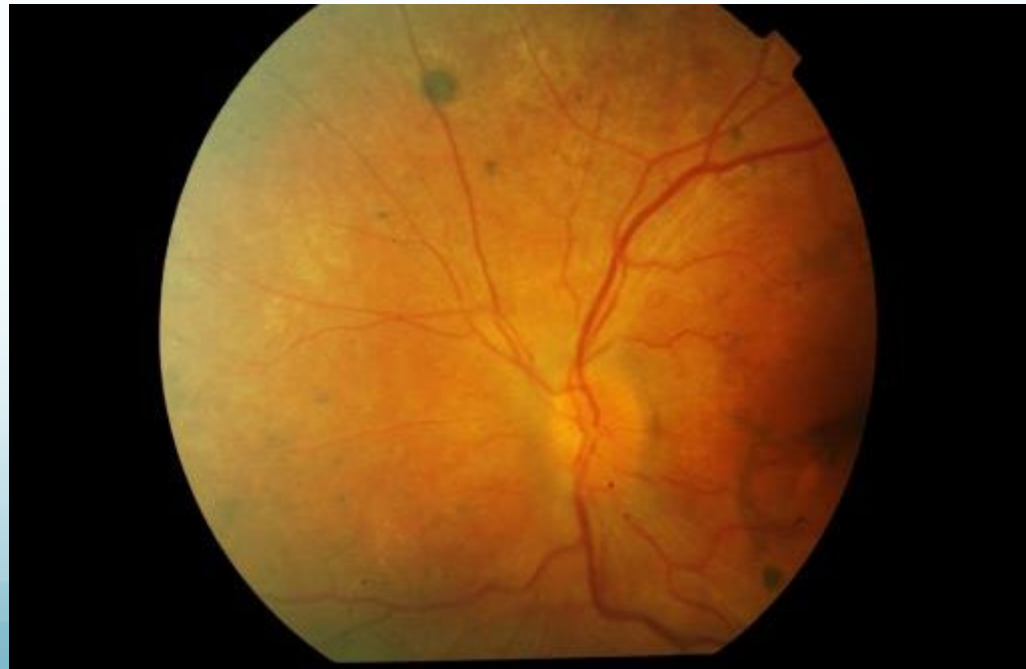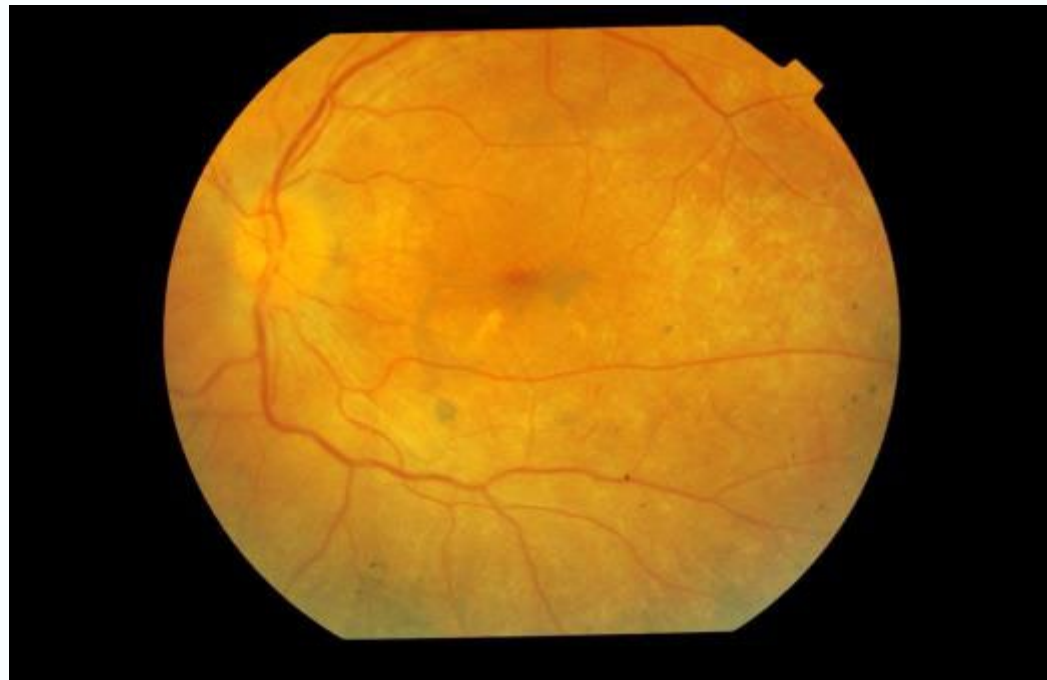Time from first visit – 1 yr

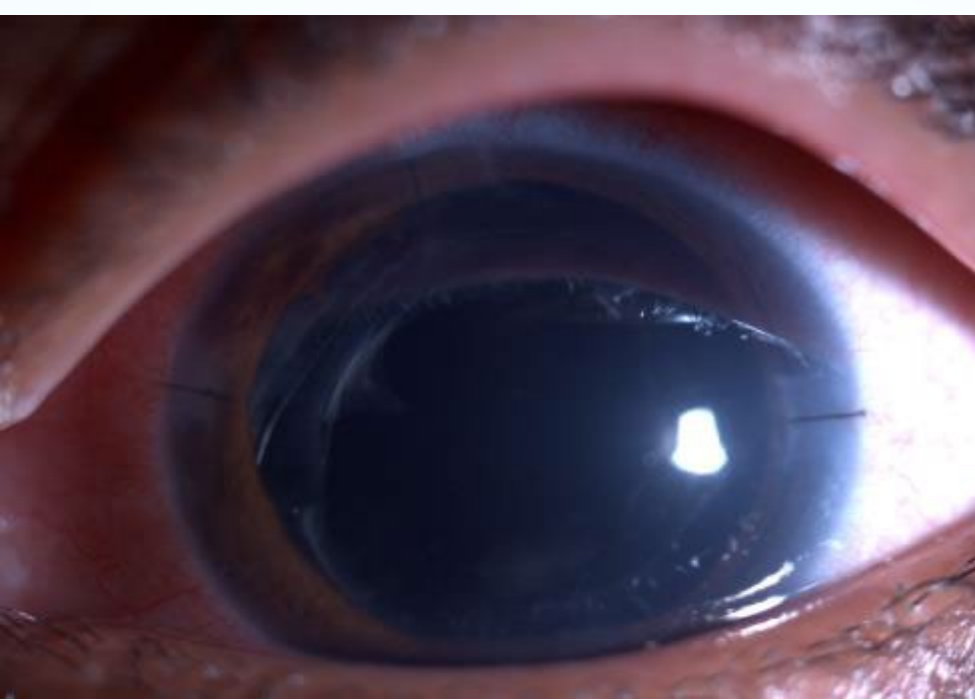


Eleven months after the
Retreatment

New issues: Cataract

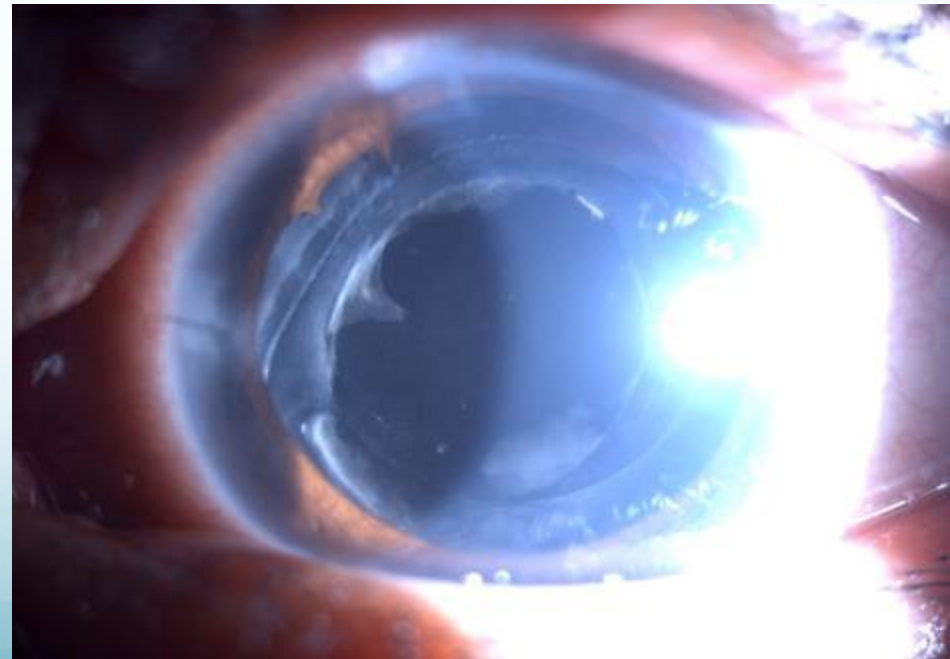
Time since first visit—2 yrs





- S/p cataract surgery.
- VA; 6/12 Nv 6/6.
- Treatment: systemic and local immunosuppression which was tapered over six months.
- During this period patient presented with high IOP hence started on anti glaucoma medication

CURRENT
VN: 6/36
MEDICATION : topical steroid
once daily ,topical antiglaucoma ,
and oral diamox.
No systemic immunosuppression .



CURRENT CHALLENGES :

PCO

GLAUCOMA : Persistent raised IOP
with increase in cup : disc ratio

WHAT NEXT?

YAG...FOLLOWED BY TRAB?

TRAB...FOLLOWED BY YAG?

YAG...FOLLOWED BY ANY OTHER
OPTION FOR GLAUCOMA?

