


Answers to Audience Questions - WSPOS Worldwide Webinar 9: Cataracts in Infants and Toddlers



WWW 9 Panellists



Yee Fong Choong



Darius Hildebrand



Ramesh Kekunnaya



Ken K. Nischal



Jagat Ram



Edward Wilson

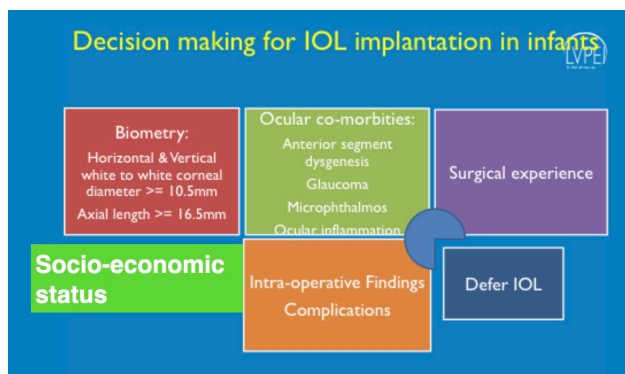


Edward Wilson (EW), Ramesh Kekunnaya (RK), Yee Fong Choong (YFC), Jagat Ram (JR), Ken Nischal (KKN)

1. What is the Panel's current take on use of IOL / contact lens in children?

EW: At ages 0 -7 months, I leave the child aphakic and use Silsoft contact lenses. I place the contact lens on the eye at the end of the surgery and do not use a patch or shield. The initial contact lens stays on the eye for 1 month, during which, the parents place prednisolone acetate drops 4 times per day. At the 1-month postoperative visit, my technician teaches the parents how to remove and clean the lens. We have the parents then remove and clean the lens weekly. For children older than 7 months, I implant an IOL at the primary surgery. When younger than 7 months, if contact lenses are not available, I implant an IOL primarily or use aphakic glasses when bilateral.

RK: Decision of IOL or not depends on patients' factors, eye factors, surgeon and the follow up, etc. I decide based on below.



If IOL is not placed, visual rehabilitation by glasses or contact lenses. This applies to all age groups be it infants or toddlers.

YFC: I prefer to implant whenever possible and tend to do so in almost all infants above 4 months old. In cases where implant is not possible, then CL or aphakic glasses. One has to consider the availability of CL and good CL practitioners in one's locality as well as the compliance of aphakic refractive correction

JR: IOL can be inserted at any age provided the axial length is 17 mm or more and corneal diameter 10 mm or more. However, some surgeons prefer IOL insertion after one year of age due to rapid changes in keratometry and axial length in the first year of life.

Contact lenses are usually preferred in patients operated for unilateral cataract to prevent diplopia and secondary surgeries (According to IATS). However, due to cost constraints in India, we prefer to insert IOL even in unilateral cases.

KKN: Most unilateral cataracts are due to PHPV. Implanting an eye with PHPV is fraught with potential complications. Therefore, in these eyes leave aphakic and try CL. Even if this fails child with both eyes will do well.

Most bilateral cataracts are due to either crystallin gene mutations or other genetic problems OR due to rubella. If due to Rubella, implanting an IOL will make the already aggressive inflammation worse. Therefore, try aphakic glasses or contact lenses. If bilateral cataracts and due to genetic issues, then I operate by 9- 12 weeks at the latest and place IOLs in the bag

2. In what age it is safe to implant Artisan IOL?

EW: I have implanted the Artisan IOL as young as age 2 years but most are age 5 and older. The Artisan IOL can be implanted at the time of lensectomy or as a secondary procedure later. For some very young children with Marfan syndrome and severe lens subluxation, I perform lensectomy first and place the child in aphakic spectacles. After monitoring eye growth (axial length) for a few years, I then implant the Artisan IOL as a secondary procedure. For children having lensectomy at age 5 and beyond, I implant the Artisan at the time of lensectomy.

RK: It can be as less as 2 years. In older children it can be performed at the time lensectomy itself.

YFC I think the size of the eyes is the main determining factor. I attempt to implant in all infants above 4 months old but for Artisan, above 2 years old. It is particularly useful in cases of poor / absent capsular support.

JR: These iris-fixated lenses can be used in aphakic children without any capsular support. They can be used around 8 years of age s after this age the myopic shift will be lesser

KKN: I personally implant these in children who have had lensectomy for subluxated lenses e.g. in Marfan syndrome. The youngest I have done is 5 years old, as I want the anterior chamber to be deep enough

3. What is the interval between cataract surgeries in bilateral cataracts in children?

EW: Usually 1 week apart but can be longer in older children. For some infants, I operate both eyes at the same time. Most commonly, the eyes are operated 1 week apart.

RK: I perform the second eye within a week's time. If child has is very high risk for anaesthesia I do bilateral surgery simultaneously.

YFC: I perform simultaneously surgery in almost all cases including on table biometry. This reduces the need for another GA. However, the surgery should be done proficiently and not too prolonged due to increasing GA risk in longer surgeries.

JR: We usually keep an interval of a week to ten days in children with bilateral cataracts.

KKN: If anaesthesia is a concern then do bilateral simultaneous but treat each eye like a new patient. If no anaesthesia issue, then minimum 4 days and maximum 7 days

4. Do you use triamcinolone for Ant. Vitrectomy?

EW: Not routinely. I use triamcinolone if I suspect vitreous is in the anterior chamber. However, in routine anterior vitrectomy, I don't use it.

RK: No.

YFC: Not in all cases. When there is doubt about vitreous clearance I would stain with triamcinolone. I also find it helpful not to pull out the torn posterior capsule as some vitreous strands may follow but rather leave it behind for removal with the vitreous cutter.

JR: Yes, we routinely use it to visualise the vitreous during anterior vitrectomy

KKN: No

5. Paediatric Anaesthesia is equally important for good clinical outcome apart from good surgical technique. What special anaesthetic techniques or parameters are most important for good outcome?

EW: I use fellowship trained paediatric anaesthesiologists and I leave the details to them. They mostly use an LMA (laryngeal mask airway) rather than an endotracheal tube.

RK: I ask the anaesthetists to keep the same level of anaesthesia till I put the last suture. End tidal CO₂ level should be less than 35. In cases of high risk infants, standby Paediatrician will be called and if needed child will be shifted to ICU.

YFC: I desire quick recovery for the infants and I prefer not to use paralytic agents for GA for speedy reversal of GA. Typically patient can go home after a morning of observation as a day care procedure. I understand this sometimes may increase vitreous pressure but this can be dealt with careful surgical management.

KKN: children must be paralyzed. Use sevoflurane for induction then switch to isoflurane (sevoflurane does not suppress sympathetic activity but isoflurane does). Keep the pCO₂ at 30 or below. This reduces positive pressure in the eye.

6. What method of undercorrection do u prefer?

EW: For IOL power undercorrection, I leave hyperopia at +6 for age 7 months to 1 year; +5 for 1-2 years; +4 for 2-3 years; +3 for 4-5 years; +2 for 6-7 years; +1 for 8-9 years and plano for 10 years and older. These children will be myopic at age 20. I also customize the hyperopia I leave, for some older children with bilateral cataracts, based on the formula I presented from our October 2019 AJO article. Furthermore, I customize based on how well I think the child will wear glasses.

RK: - I leave hyperopia at +8-9 D for age 2-6 months, +6-7 D 7-months 1 year, +5D for 1-2 years, +4 for 2-3 years, +3 for 4-5 years, +2 for 6-7 years; +1 for 8 years, plano for 9 years and older. Please see - *Sachdeva V, Katukuri S, Kekunnaya R, Fernandes M, Ali MH. Validation of Guidelines for Undercorrection of Intraocular Lens Power in Children. Am J Ophthalmol. 2017;174:17-22.* Additionally, in unilateral cases and children with CVI, I undercorrect less.

YFC: 4-6 months (+3 to +4). 6-12 months (+3), 12-24 months (+2) and >24 months (+1 to +2). The main reason for this rather "undercorrection" is to reduce risk associated with high ametropia in this highly vulnerable age. I am happy to deal with the consequent high myopia in the future with sulcus implants e.g. ICL or surface refractive error. Also this high myopia is not necessarily of the pathological types.

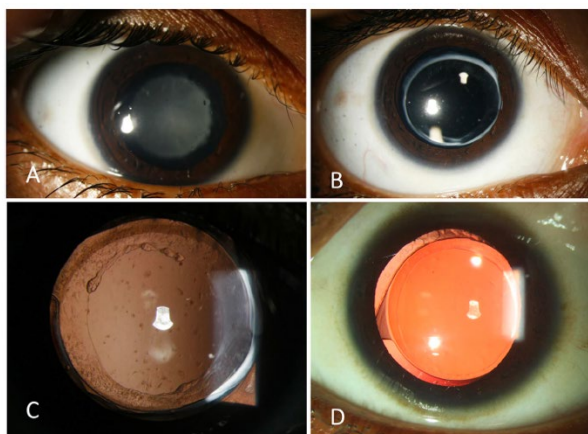
JR: We prefer 20% undercorrection in children up to 2 years and 10% in children >2-8 years of age

KKN: <3 month +12, 3 - 6 months +8, 6 - 12 months +6, 12 - 24 months +5, 24 - 36 months +4, 36 - 48 months +3, 4 yrs. -7 yrs. +2, 8 yrs. to 12 yrs. +1

7. Does anyone use zeptorrhesis?

EW: The current Zepto makes a capsulorhexis that is too big for children (in my opinion) since the elastic capsule of the child expands the size of the Zepto rhexis. The company that makes Zepto has promised a paediatric sized Zepto but they have not delivered.

RK: We have some experience with this. We have suggested the company to make smaller sized nitinol ring, so that we can use it infants as well. Please see - *Chougule P, Warkad V, Badakere A, et al Precision pulse capsulotomy: an automated alternative to manual capsulorhexis in paediatric cataract BMJ Open Ophthalmology 2019;4:e000255. (paper attached)*



YFC: No. I think Dr Ramesh have some experience with this technology

JR: We have no experience of Zeptorrhesis

KKN: Not me

8. Any place for femto cataract in paediatric cases?

EW: The Zeimer femtosecond laser is fully portable and can be used in the sterile environment of general anaesthesia. It may be useful for increasing precision of both the anterior and posterior capsulorhexis size and shape. This is needed for techniques such as Bag-in-the-Lens. Cost is a major problem and it is not needed for the cataract removal itself.

RK: No experience with this. Cost is prohibitive I guess.

YFC: In my opinion very limited due to the small size of the infant eyes, cost of procedure, weakened capsular edge, inability to perform posterior capsulorhexis, the difficult logistics etc. Even if used, typically in much older patients where surgical capsulotomy is not as challenging

JR: Yes, femto cataract can be used in paediatric cases (especially subluxated and intumescent white cataracts), though it requires shifting of the patient from one OR to the other

KKN: if there is one in the OR, then yes

9. How early (at what age) do you do a clear corneal incision?

EW: I do clear corneal incisions for all ages, even those operated at 4-6 weeks of age.

RK: My preferred incision is clear corneal for all ages.

YFC: for infants and toddlers I prefer limbal. Totally clear cornea only in children above 5 years' old

JR: All ages

KKN: always do corneal incision, but close to limbus

10. How do you deal with rhexis in very shallow AC?

EW: I use tight-fit incisions, a micro-forceps (small incision capsulorhexis forceps) and highly viscous cohesive visco-elastic (OVD- ophthalmic visco-surgical device)

RK: I use cohesive viscoelastic. AC can be shallow in cases of intumescent lens (lens thickness more than 3.8) as well. In these type of cases, it is a good idea to aspirate a small amount of lens matter and then proceed with capsulorhexis.

YFC: Manual capsulorhexis with 23 G forceps through a MVR stab corneal incision. Intracameral Adrenaline for adequate pupil dilatation.

JR: We use vitrector assisted anterior capsulorrhexis in patients with shallow anterior chambers

KKN: I use Healon 5 to deepen AC

11. Is hydrodissection necessary?

EW: In my view, hydrodissection is not necessary for paediatric cataract surgery. I don't hydrodissect if there is any chance of a posterior capsule weakness (such as posterior lenticonus/lentiglobus or posterior polar cataract). In other types of cataract, hydrodissection may speed up the cortex aspiration but not enough to say that it is required.

RK: In my opinion hydro dissection is not necessary (it should be avoided in post lenticonus etc.). I advise surgeons to spend significant time on polishing the under surface of anterior capsule, bag up till equator. (this may prevent excessive LEC proliferation)

YFC: I do hydrodissection to aid the lens aspiration

JR: No, it is not necessary. The surgeon can use the irrigation-aspiration cannulas itself for hydrodissection

KKN: No

12. Does the panel have any tips to reduce positive vitreous upthrust in infants?

EW: Tight-fit incisions (closed-chamber techniques) and using a Venturi-pump machine that has a fluid pump rather than a gravity-fed irrigation.

RK: Closed anterior chamber with tight fit side port incisions and et CO2 level less than 35 will help with reducing the vitreous up thrust.

JR: A good cohesive viscoelastic use during surgery and adequate anterior vitrectomy can help in reducing vitreous up thrust in infants

KKN: See Q 5

13. What are the possible causes of IOL opacification within 48 hours post paediatric cataract surgery?

EW: I have not seen any IOL opacification but I have read about specific IOL brands that are prone to this.

RK: Not seen this phenomenon, but could be due to intense inflammation causing membrane over the IOL esp. with hydrophilic IOLs?

YFC: I haven't encounter this. I use hydrophobic acrylic single piece IOL. I avoid hydrophilic acrylic due to opacification issues

JR: Excessive inflammatory reaction due to repeated iris handling can lead to membrane over IOL as early as within 48 hours

KKN: I have never seen this, but I would worry that something was injected into the eye by accident

14. I use acrylic single piece due to cost issue at Nepal. We do not have 3 piece and single piece hydrophobic lens. We observed very bad PCO in young children. Would it be better to replace with PMMA in cases that need large incisions? In such situation what would be the better choice?

EW: I do not think that a switch to PMMA would decrease the PCO rate and the stiff PMMA material is more difficult to get into small capsular bags. If high rates of PCO are found, I would recommend a posterior capsulorhexis and anterior vitrectomy even in the older children.

RK: We have used PMMA smaller diameter IOL's in the past. It works very well in the long run, only issue is that incision size will bigger in these kinds of scenario.

YFC: The current best practice is still hydrophobic acrylic IOL. PMMA is too large which necessitates a large incisional wound which is disadvantageous resulting in higher risks of iris prolapse, post op inflammation and more suturing.

JR: Hydrophobic acrylic IOL's are the best choice in young children to avoid PCO. However, if unavailable, PMMA IOL's can also be used

KKN: If the child's eye is big enough, then I would do posterior rhexis that is generous and use the foldable lens; anterior vitrectomy is very important the way it was described in the webinar

15. Could you give tips on doing biometry intraoperatively? How do you get accurate K readings, axial length, and best formula to use in computing IOL power?

EW: For biometry in the operating room, I use a portable handheld keratometer and A-scan immersion ultrasound. I have customized my lens constant and use the Holladay 1 formula. We are in the process of switching to the Barrett formula. I often run several formulas before making a final choice.

RK: I use portable handheld keratometer and A scan. Please do not use eye lid speculum. Your assistants can open the eye lids gently. Keep the cornea always moist. (do not check the IOP first or instil any other eye drops) No formula is perfect in terms of prediction errors. In our hands SRK 11 / T works very well. Please see: (a) Sachdeva V, Katukuri S, Kekunnaya R, Fernandes M, Ali MH. Validation of Guidelines for Undercorrection of Intraocular Lens Power in Children. *Am J Ophthalmol.* 2017;174:17-22. & (b) Kekunnaya R, Gupta A, Sachdeva V, Rao HL, Vaddavalli PK, Om Prakash V. Accuracy of intraocular lens power calculation formulae in children less than two years. *Am J Ophthalmol.* 2012;154(1):13-19.e2.

YFC: We have to recognise that it is difficult to perform good biometry in children. Older children may tolerate OCB e.g. IOL master so I always try. Some may also tolerate table top autoK which are more accurate than most hand held versions. For AL using ultrasound, I perform immersion using the Prager shell. I use SRT-K for calculation. I tend not to worry too much since the refractive status would change anyway. I just don't want serious surprise of implanting an IOL that is way out.

JR: Accurate K readings can be obtained using a hand-held keratometer before putting the speculum and after wetting the cornea with balanced salt solution/saline. Accurate axial length can be obtained using an immersion A-scan which precludes the indentation of the cornea. Best formula in infants is SRK-T and Holladay I according to the Infant Aphakia Treatment Study

KKN: I use a handheld (nidek) keratometer. AL is done by contact method. Use Hoffer Q if <21 mm AL and SRK-T for eyes over 21 mm

16. Why are no paediatric sized IOLs? All of them are of "adult size".

EW: In the PMMA era, we were all convinced that paediatric down-sized IOL would be needed. However, modern foldable acrylic IOLs adapt reasonably well to the smaller capsular bags – even in a 2-month old. The Artisan IOL does come in a smaller version for microphthalmia/micro-cornea.

RK: Foldable IOL's fit very well even in small infants. However, in microcornea and microphthalmos cases we need customized lenses, some companies make it.

YFC: Ask the industry :) I think it is not commercially viable and getting regulatory approval is just too difficult and costly. This is the case with almost all medicines and eye drops used in children/ infants. They are essentially off label use.

JR: Some companies in India (Mini Well) make IOLs with 10.75 mm overall diameter which can be used in paediatric cases

KKN: With foldable lenses, it's not so much of a problem. Smaller lenses should be considered, if made of PMMA. These lenses should have a total diameter of 10.5 mm with an optic of 5 mm

17. Is vision as an infant more important or when as an adult? Why aim for anisohyperopia?

EW: Vision as an infant is more important. However, families also want us to prevent high myopia later if we can. If the surgeon feels that glasses compliance will be poor, then aiming for emmetropia at surgery makes sense – but the family needs to know that an IOL exchange will be needed later. Anisohyperopia is very well tolerated in children with unilateral cataracts and the image does not degrade as much as you might think when the glasses are off. Many of these children spend half of the day being patched. Aiming for emmetropia as an adult is, of course, best tolerated in bilateral cataracts and I often reduce my hyperopic aim in unilateral cases to reduce the glasses power some.

RK: Vision infancy is more important. However, in infants the axial length grows very fast in the initial few months. Hence in unilateral cases I tend to under correct less. Myopia in later part of the life can be tackled.

YFC: I agree. Therefore, I do not aim for high hyperopia so to avoid myopia in the future. I prefer near emmetropia when the child is still young to reduce risk of severe amblyopia and deal with the myopia later in life

JR: We aim for moderate hyperopia to offset the myopic shift which occurs with the growth of the eyeball as the child becomes older

KKN: The normal eye has 3 growth phases: 0 - 18 mths - Rapid growth of 3.5 - 3.75 mm, 2 yrs. - 8 yrs. - growth of 2 mm, then 8 yrs. to 16 yrs. - growth of 2 mm. The anisohyperopia is only a problem for a very short time and if corrected with glasses, it should not be an adverse event. If a child is left at or close to emmetropia as an infant or toddler, then you will get anisomyopia before 8 yrs. of age. So I choose to under correct

18. What is the panel's post-op regimen by ages?

EW: in surgery, I inject non-preserved moxifloxacin (0.1 cc = 500 ug) and dexamethasone (0.1 cc=0.6 mg). Post-op I use topical pred. acetate drops 4 times per day for 4 weeks at all ages. I add atropine 1% once per day for 30 days in children who are operated in the first year of life.

RK: In infants, s/c dexamethasone, post operatively Prednisolone acetate 6-10 times per day tapering dose over 4-5 weeks, atropine eye drops once a day for 3 weeks and Moxifloxacin eye drops 4 times per day for a week.

YFC: Immediate post op SC dexamethasone and intracameral Moxifloxacin. Post op drops: Topical steroids - Predforte 1% 2 hourly 3 days then QID for 3-4 weeks. Gutt Moxifloxacin QID, Gutt Atropine 1% BD 1 week

JR: We give topical steroids 8-10 times/day in children < 1 year and 6 times/day in patients >1 year of age. Topical antibiotics and cycloplegics are given four times/day and thrice/day for a period of 2 weeks

KKN: Tobradex - qid, tid, bid, once daily and stop (every 1-week reduction); cycloplegic - once daily or twice daily (depending on amount of pigment) for 2 weeks

19. What is your setting parameter in Bimanual IA machine to aspirate viscoelastic after PPC, anterior vitrectomy and implanting IOL?

EW: I use a Venturi pump machine with irrigation set at 30 and aspiration at 300.

RK: Irrigation of 25-30 with aspiration rate at 250.

YFC: I use manual aspiration using Simcoe cannula for greater and more delicate control

JR: We use the vitrector in the IA-Cut mode to aspirate the viscoelastic after PPC, AV and implanting IOL.

KKN: Bottle height - at very lowest, aspiration - max. 500 mm Hg and then enter with aspiration first, then introduce irrigation (which is very little)

20. Does Dr. Wilson worry about anisohyperopia? Leaving a child hyperopic crippled as a child?

EW: In the article below, we achieved a consensus from world-wide experts for leaving hyperopia at the time of cataract surgery. Glasses are needed along with patching (if unilateral). *Massimiliano Serafino, Rupal H. Trivedi, Alex V. Levin, M. Edward Wilson, Paolo Nucci, Scott R. Lambert, Ken K. Nischal, David A. Plager, Dominique Bremond-Gignac, Ramesh Kekunnaya, Sachiko Nishina, Nasrin N. Tehrani, Marcelo C. Ventura. Use of the Delphi Process in Paediatric Cataract Management. British Journal of Ophthalmology, 2016;100: (5) May, pages 611-615.*

KKN: See Q 17

21. Please share link to the White Paper Dr. Wilson mentioned.

EW: I will send a PDF and it can be included if the organizers want to send it - J Cataract Refract Surg - Vol 33, November 2007

22. When (after cataract surgery) will you give glasses in aphakic child?

EW: At 2-4 weeks after surgery

RK: 1 week after second eye surgery.

YFC: As soon as possible.

JR: We give glasses after 2 weeks' post-surgery in an aphakic child

KKN: First day post-op; we have standard glasses made that have different aphakia prescriptions; we have unilateral and bilateral ones. We loan these to parents and then give accurate prescription at 2 weeks' post-op

23. In the case of a 6 years-old child with a monocular cataract, would you implant a multifocal IOL in order not to lose stereoscopic vision?

EW: no, I would use a monofocal IOL and prescribe a bifocal. Multifocal lenses have too much downside when placed unilaterally in a growing eye. There is loss of contrast sensitivity and the optics are bad when the child grows and myopia occurs. Also, in the USA, there is extra cost that the young families can't afford.

RK: No

YFC: I won't implant multifocal in 6 years old as the magnitude of refractive status change is high with age. Multifocal only works well if the refractive correction is near emmetropia. Otherwise the contrast sensitivity loss is high.

JR: Multifocal IOLs are implanted after 8 years of age as before that there are chances of myopic shift occurring with increase in the growth of the eyeball

KKN: No

24. Do u recommend consider multifocal IOL in a child around 8 years of age?

EW: no – not until the end of eye growth.

RK: No

YFC: I only consider multifocal in patients above 12 years' old

JR: Yes, we recommend multifocal IOL in a child around 8 years of age due to less chances of myopic shift in these patients

KKN: No

25. If in unilateral cases, the normal eye is myopic, would we still want to aim for the usual amount of undercorrection?

EW: These decisions are made on a case-by-case basis but the myopic shift after IOL is different than the myopic shift in the phakic eye. The phakic eye has a changing crystalline lens that can offset most of the axial growth. The IOL eye will see much more myopic shift with each mm of axial eye growth.

RK: This an exception to normal infant with paediatric cataract. I will take a decision on case to case basis. Refractive error status of the parents also matters in taking the final IOL power which can be implanted.

YFC: Depending on the age. I will not want too much anisometropia as this is amblyopiogenic.

JR: No, we would not aim for the usual amount of undercorrection but lesser undercorrection to maintain a balance with the other eye which is myopic and avoid diplopia

KKN: depends on age of child – if 6 yr. old, then aim for a target that is +2.00 myopia of the other eye. Younger child, aim for +3.00 myopia of the other eye

26. Clinically how do we recognize a rubella cataract? And what are the surgical challenges in rubella cataract?

EW: I don't see rubella cataracts in the USA.

RK: Rubella infants will have associated microcephaly, cardiac abnormalities, other ocular associations such as microcornea, bald iris, synechiae and total or partial cataract (with calcification etc.). Pupil may not dilate fully hence one might have to use iris hooks, cataract may be hard occasionally, children are high risk for anaesthesia, pupilloplasty may be required in few cases. Post operatively atropine and intense topical steroid is a must.

YFC: The child may have the classical triad. Look for hearing loss and pigmentary retinopathy

JR: Rubella cataracts are usually total white cataracts. Absence of red glow requires staining with trypan blue dye and extension of the rhexis can be prevented by using cohesive viscoelastic

KKN: look for signs of rubella syndrome – microcephaly, heart murmur and cataracts. There is much more inflammation in the eyes post surgery and the pupils do not dilate very well

27. Can you clear lens epithelial cells or visual axis opacification using YAG laser in children?

EW: no, not very well – these usually require surgery.

RK: Yes, possible in some older children esp. if the VAO is minimal. Generally, need surgery.

YFC: yes, if they cooperate. Most would cooperate if the YAG contact lens is not used. It is possible to perform YAG capsulotomy without the contact lens. Children are more tolerant of non-contact lens YAG than if a contact lens is used.

JR: Nd-YAG laser can be used for children > 8 years of age

KKN: YAG capsulotomy is not easy in children at all. In my experience, you cannot clear lens epithelial cell regrowth very well with YAG. Therefore, I do TIPP posterior rhexis in posterior capsule up until age 16 yrs. without anterior vitrectomy

28. When the primary post. capsulorhexis is done after IOL implantation, if the post. rhexis extends, is the IOL removed and repositioned in the sulcus? Or is it left in the bag?

EW: It would depend on whether the IOL appears to be stable. Reverse optic capture could also be considered (optic captured in the anterior rhexis).

RK: Depends upon the stability of IOL. If IOL is unstable, better to place it in the sulcus (of course the 3-piece IOL)

YFC: If you are using a three piece IOL, then you can consider sulcus and posterior IOL capture. If it is a single piece, then the IOL may need to be replaced with a 3-piece IOL for sulcus implantation. If the anterior capsulotomy is of a good and appropriate size, and the haptics are secured in the capsular bag fornices, then anterior capsular optic capture can also be considered.

JR: IOL is left in the bag, only if it is well centred. If it decentres, it is repositioned in the sulcus

KKN: I never do the PPC after IOL insertion from the limbal wound

29. Would you perform a Bilateral cataract surgery in an infant in the same session?

EW: yes, we sometimes do this in babies under 3 months of age when the anaesthesia is riskier. We treat each eye with separate set of instruments and separate prep and drape.

RK: Yes, very rarely. In cases where infants are very high risk for anaesthesia.

YFC: Yes, this is my usual practice. Please see above

JR: No we do not do bilateral simultaneous surgery in bilateral cataract

KKN: only for medical / anaesthesia reasons

30. When is best to operate on a child with unilateral congenital cataract?

EW: 5 - 6 weeks of age.

RK: around 5 weeks of age.

YFC: Depending on cataract density and age of discovery. Generally, as soon as possible

JR: It is best to operate a child with unilateral cataract at the age of 4 - 6 weeks

KKN: 6 weeks of age up to 8 weeks, depending on appearance of lens

31. Dr Ken: Do you implant IOL in all aniridia cases? As shown the picture of Posterior capture of IOL by you.

KKN: So far I have always managed to do so. I do think IOL is better. These children do not tolerate CL because of the limbal stem cell deficiency, which gets worse with CL wear

32. Do you do simultaneous surgery in bilateral cataract?

EW: the only age that I will consider bilateral simultaneous cataract surgery is in infants.

RK: please see Q 29

YFC: Yes, this is my usual practice. See above

JR: No, we do not do bilateral simultaneous surgery in bilateral cataract

KKN: not sure I understand - Do you mean bilateral simultaneous? If so, only on medical / anaesthesia grounds

33. What are the specifications of the micro capsulorrhexis forceps used and preferred by the panel?

EW: 23 gauge forceps that fit through a paracentesis.

RK: 23 gauge micro capsulorrhexis forceps through side port incision.

YFC: 21 or 23 G Kawai microcapsulorrhexis forceps

JR: We do not have any special preference for the micro capsulorrhexis forceps

KKN: I use the ones made by John Weiss or Duckworth Kent

34. What is the relative size of the anterior and posterior capsulorrhexis? Which should be larger?

EW: PCCC is ideally 1 mm smaller than the ACCC.

RK: ACCC should be around 5.5 mm and PCCC should be around 4.5 mm

YFC: Anterior to be larger. Anterior 5 - 5.5 mm Posterior 3.5 - 4 mm

JR: The relative size of anterior capsulorrhexis should be around 5 - 5.5 mm and of the posterior capsulorrhexis should be 3 - 3.5 mm

KKN: anterior should be 5 mm and posterior 4 - 5 mm

35. What is the panel's opinion on optic capture after 2 months of traumatic cataract in young patients with poor vision? Would you do away with the optic capture here?

EW: if you mean a "pupil capture" of the optic, I would not leave it since it may cause chronic low grade inflammation.

RK: Best to leave it if the IOL is stable.

YFC: In traumatic cataract with ruptured capsule but limited zonulysis, 3 piece IOL in sulcus with optic capture is sometimes necessary. If poor capsular support due to extensive zonulysis, one can consider iris clip/ claw lens e.g. Artisan if the anterior chamber is able to accommodate.

JR: Refraction should be done and if myopic shift is present, then the optic capture should be operated upon

KKN: not sure of the question. Optic capture should be done when the anterior capsule is disrupted such that it will not hold the IOL back; by doing optic capture you prevent IOL / iris capture

36. Dr. Ed Wilson: When do you choose not to do a vitrectomy?

EW: sometimes in older children (above age 4) I will perform a manual PCCC and no vitrectomy

RK: In children older than 8 years' old

37. Are there any pearls / tricks for avoiding widening of the posterior capsulotomy during IOL insertion?

EW: I like to do the posterior capsulotomy after I am sure that the IOL is already securely placed into the capsular bag.

RK: Leading haptic should be guided into 6 o'clock equator area and make sure that most part of IOL is in the bag, the trailing haptic and remaining optic should be gently nudged into the bag. Additionally, one should create a round, regular PCCC.

YFC: I use the two incision push pull technique (TIPP). It is easily replicable and safe. The two stab incisions ensure the diameter of the posterior capsulotomy and acts as a fail safe

JR: Proper distention of the capsular bag with cohesive viscoelastic is essential to avoid widening of the posterior capsulotomy

KKN: Use viscoelastic in the bag. Put the leading haptic just under the anterior capsule, then open the IOL in the anterior chamber. Using a Kuglen hook or similar (Sinsky etc.) knock the optic into the bag. Then put the trailing haptic into the bag. This way there is no tension on the posterior capsule opening

38. When doing optic capture, shouldn't it be a three-piece IOL?

EW: yes

RK: Yes

YFC: Yes, this is desired

JR: Yes, a three piece IOL should be preferred for optic capture as it entails better stability

KKN: absolutely or a PMMA lens

39. How would you manage corneal tear with traumatic cataract up to 8 yrs. of age?

EW: if possible, I like to close the corneal laceration first, treat with topical steroids and defer the cataract surgery for 2-4 weeks (even if the lens is ruptured). If this delay can occur (and it is not always possible) then there is much less inflammation and fewer cell deposits on the IOL.

RK: Repair the corneal tear first and cataract surgery later (unless there is severe damage to anterior capsule and significant amount of lens matter in the anterior chamber). Sometimes we need to perform the cataract surgery at the same time and use keratometry of the other eye for IOL power calculations.

YFC: Of course this depends on the extent of the laceration. Generally, I would repair the corneal tear first then I would perform the lens surgery at a later stage. However, if the integrity of the sutured wound is good and the view clear, then lens surgery can be at the same time. Clearing all the lens matter is crucial to reduce severe post op inflammation. Oral steroids may be considered. Adequate antibiotic prophylaxis is also important

JR: The corneal tear should be repaired first followed by traumatic cataract surgery with/without IOL implantation in the second sitting provided there is no anterior capsular tear with cortical matter touching the endothelium, in which cases lens matter aspiration needs to be done in the same sitting itself to avoid corneal decompensation and lens-particle glaucoma

KKN: Repair cornea with 10/0 nylon. Also recommend that you consider reading the paper I wrote about the 'Banded Technique for traumatic cataracts.: Chowdhary S, Nischal KK. Banded technique for pediatric traumatic cataract surgery. *J Cataract Refract Surg.* 2019;45(1):8-10.

40. What is the best age for IOL insertion?

EW: 7 months and older

RK: Depends on case to case basis, even at 2 months, IOL can be implanted in selected case. Please see the answer to Q 1.

YFC: I consider IOL implant in children above 4 months old. The older the child, the less complicated the implantation

JR: IOL can be inserted at any age provided the axial length is 17 mm or more and corneal diameter 10 mm or more. However, some surgeons prefer IOL insertion after one year of age due to rapid changes in keratometry and axial length in the first year of life.

KKN: Depends on the type of cataract. If bilateral congenital with equal effect of cataract, then I will wait until 8-10 weeks and then do 1 eye followed by other eye 3 days later. If unilateral, usually if congenital due to PHPV. I do not put IOL in PHPV eyes due abnormal vessels. If unilateral and posterior lenticonus, can wait till 8 weeks and then I would put IOL if normal eye otherwise

41. How do you go about your rhexis?

EW: Highly viscous OVD to flatten the dome, pull more toward the centre, re-grab often, aim for slightly smaller than in an adult.

RK: Make sure that pupil is dilated, AC is deep, make a tiny nick in the anterior capsule, with the help of micro rhexis forceps begin the rhexis with pull toward the centre, grab and regrab and one should aim for smaller rhexis which eventually expands by 1 mm or so. It helps to be ambidextrous here.

YFC: I perform a modified TIPP technique. I find this technique consistent and reproducible and safe.

JR: We start with a 26 G cystitome and complete the rhexis with a utrata forceps

KKN: I use the Two Incision Push Pull Rhexis (TIPP Rhexis). Please see YouTube video https://youtu.be/dDomA8Qg_zE

Also see: Hamada S, Low S, Walters BC, Nischal KK. Five-year experience of the 2-incision push-pull technique for anterior and posterior capsulorrhexis in pediatric cataract surgery. *Ophthalmology*. 2006;113(8):1309-1314.
Nischal KK. Two-incision push-pull capsulorhexis for pediatric cataract surgery. *J Cataract Refract Surg*. 2002;28(4):593-595.

42. Would you insert an IOL for a 6-month-old with unocular cataract?

EW: yes, if I felt that the parents could not manage a contact lens but no if I felt the parents could handle the contact lens. Predicting the power of a secondary IOL at age 4 or 5 is better than predicting the power of an IOL at age 6 months.

RK: Yes, if the child passes selection criteria. Please see answer to Q 1.

YFC: Yes

JR: We would prefer keeping the patient aphakic with the use of contact lens in patients with unocular cataract. However, due to cost constraints in India, we insert an IOL even in unilateral cases and subject the child to amblyopia therapy using part time occlusion

KKN: if the eye was normal and not PHPV, yes

43. Management of cataract in amblyopia patient?

EW: patching after surgery is the key.

RK: Optical rehabilitation with glasses, patch therapy, visual stimulation exercise, strabismus surgery if required etc.

JR: We operate for the cataract even in patients of amblyopia and then carry out amblyopia therapy with part time occlusion.

KKN: Operate and patch good eye, even if over 8 yrs.

44. Best age to insert IOL?

EW- 7 months or older.

RK: Depends on case to case basis, unilateral or bilateral cataract etc. Please see my answer to Q 1.

YFC: As above

JR: IOL can be inserted at any age provided the axial length is >17 mm and corneal diameter > 10 mm. However, some surgeons prefer IOL insertion after one year of age due to rapid changes in keratometry and axial length in the first year of life

KKN: see previous answers

45. Up to what age would you consider doing the push-pull?

EW: it is a good technique for any age; but it is the personal preference of the surgeon. Practice makes perfect with all CCC techniques.

RK: I do not perform that technique, but I guess it can be done at any age. Dr. Nischal can comment on it.

YFC: up to 2 years old for anterior capsule and 5 years old for posterior capsule. Thereafter, normal manual capsulorhexis is normally safe.

JR: Two incision push-pull capsulorhexis is a reliable method for producing a consistent-size capsulorhexis opening in both anterior and posterior capsulorhexis. Though we have not used it, studies show that it can be used in children from 4 weeks to 18 years of age

KKN: I do up to 16 yrs., but it is less elastic then, so you are doing two half rhexes and joining them. Please see Q 41

46. In a study in Egypt that was published in 2018 we found that the capture group although had a larger central clear area showed decent ration compared to on the bag implantation group. That is in a 6 months follow up. I wonder what the panel think about that?

EW: Optic capture techniques are harder for surgeons to learn but studies like this will encourage more surgeons to use optic capture more often.

RK: My comments are in this open access article. Kekunnaya R. Commentary: To capture or not in pediatric cataract surgery? *Indian J Ophthalmol.* 2020;68(1):89.

YFC: Yes. Read this paper. I don't perform optic capture in most of my cases other than in selected scenarios. I suppose if the original capsulotomy is decentred this may cause increased rate of decentration.

JR: Decentration in posterior optic capture occurs only when the posterior capsulotomy is bigger than the size of the optic

KKN: do you mean that there was more decentration? that is not my experience

47. For the panel, any tips for doing posterior optic capture?

EW: take extra care to perform a perfectly sized PCCC. When doing a PCCC, put the OVD in the sulcus and don't overfill. If the OVD is placed in the bag, the PC is pushed back in a concave shape and this will make the PCCC hard to do.

RK: PCCC should be round and regular and not too large or small. Deepen the anterior chamber. Please do not over inflate lens bag. Gently tuck the optic edges all around.

JR: The size of the posterior capsulotomy should be slightly smaller than the size of the optic, if a posterior optic capture is being planned. Moreover, adequate anterior vitrectomy will prevent the upthrust of the vitreous in children who are known to have positive vitreous pressure

KKN: make the posterior rhexis large (around 4 - 5 mm). I do an anterior vitrectomy. Use your second instrument to tilt the leading edge of the optic under the capsule, and push down and forward; then once this is under the PC, push back on the trailing edge of the optic to get that under the PC

48. What is the youngest age you have done a YAG capsulotomy?

EW: age 4

RK: 4 years

YFC: 3 years old. Without contact lens. The patient did really well!

JR: The youngest age for us has been 5 weeks old infant

KKN: I used to have a supine YAG, so have done 2 yr. olds under GA

49. Please share the formula of Dr. Wilson!

EW:

$$\text{Postoperative AL} = 1.93 + 0.91 \times (\text{baseline AL}) - 0.07 \times (\text{baseline age}) + 0.14 \times (\text{age at follow-up}) - 0.005 \times (\text{baseline age}) \times (\text{age at follow-up})$$

50. Could you give tips on doing biometry intraoperatively-how do you get accurate K readings, axial length, and best formula to use in computing IOL power?

EW: keep the cornea moist – it often dries out during the induction of anaesthesia (tape the eyes during induction of anaesthesia). Use a portable handheld keratometer and then I like immersion A-scan better than contact A-scan. I also like the Holladay 1 formula for children.

RK: Please see the answer to Q 15.

YFC: See above

JR: Accurate K readings can be obtained using a hand-held keratometer before putting the speculum and after wetting the cornea with balanced salt solution/saline. Accurate axial length can be obtained using an immersion A-scan which precludes the indentation of the cornea. Best formula in infants is SRK-T and Holladay I according to the Infant Aphakia Treatment Study

KKN: see previous question about this

51. Does the panel have any pearls / tricks for avoiding widening of the posterior capsulotomy during IOL insertion?

EW: Place adequate OVD so that the lens does not come in contact with the PCCC.

RK: Please see my answer to Q 37

YFC: TIPP technique – the stab incisions demarcate the diameter of the posterior capsulotomy. Always pull or push towards the centre.

JR: To avoid this, try putting the leading haptic into the capsular bag beyond the inferior edge of the posterior capsulotomy after distending the capsular bag with a cohesive viscoelastic

KKN: see previous question about this

52. How much viscoelastic is important to completely fill the pocket for posterior capsulorhexis?

EW: when doing PCCC manually, do not fill the bag with viscoelastic (OVD). Rather, put it in the sulcus and push the anterior capsule in contact with the posterior capsule – don't over fill the centre – try to keep the posterior capsule flat and not concave.

RK: During PCCC best not to overfill the lens bag. Deepen the anterior chamber. Keep the PC flat and this will help in performing manual PCCC without any difficulty.

YFC: I don't overfill as I use the TIPP technique since overfilling results in an oblong rhexis. Fill until the posterior capsule is slightly bowing back a little, but not too much.

JR: Small amount of viscoelastic is required to fill the pocket for posterior capsulorhexis

KKN: NO; in fact, you must not fill the bag when doing posterior rhexis, you must deepen the Anterior chamber without filling the bag

53. Do you routinely use triamcinolone to visualize the vitreous when you do anterior vitrectomy?

EW: no. I use it to visualize vitreous when I suspect it is in the AC.

RK: No

YFC: See above

JR: Yes, we routinely use it to visualise the vitreous during anterior vitrectomy

KKN: No

54. What are your thoughts on optic capture with fusion of both AC and PC with haptic in the sulcus?

EW: This is called "bi-capsular capture" and I think it is a good alternative.

RK: I think it's a good idea, but might be difficult to achieve practically.

YFC: I don't routinely perform this unless I cannot implant in the bag. 3 piece IOL is not designed for sulcus fixation so I still prefer implantation in the bag

JR: It can be done though caution should be exercised while doing it to prevent IOL drop in the vitreous. It is a good technique for prevention of PCO

KKN: I don't like leaving haptics in the sulcus unless I have no other choice

55. Do you prefer vitrectomy through parsplana?

EW: yes

RK: No. I prefer through anterior route except in PFV when there is involvement of post segment as well.

YFC: No, I perform anterior vitrectomy through limbal incisions

JR: We prefer vitrectomy through the limbal route being anterior segment surgeons

KKN: No

56. Do you do something extra for myopic pre-schoolers?

EW: not sure about the question but no, I don't think I approach them differently.

RK: Not sure about the question

JR: We give such patients Atropine drops 0.01% to prevent amblyopia progression

KKN: No

57. Dear panellists, how often do you implant aniridia IOL? When do you choose to implant regular IOL in an aniridia eye? And why?

EW: Aniridia and cataract early in life are not common but I do implant IOLs in this setting.

RK: Yes, I do implant in aniridia cases, if and only, corneal diameter and bag size is good enough. I use a single piece IOL in the bag. The dough nut of VAO acts as a barrier for excessive light entry in these children.

JR: In our centre, we implant aniridia IOL once in 2-3 months. Regular IOL in an aniridia eye is only done when the patient is not affording. In such cases, we ensure for an in-the-bag placement of a regular IOL and aim for a slightly smaller anterior capsulorhexis (without capsular polishing) which can later opacify and prevent glare and photophobia to the patient.

KKN: I always implant and use MA60AC IOL

58. Do you all do vitrectomy before IOL implantation or after IOL implantation?

EW: after IOL implantation.

RK: Usually before IOL implantation.

YFC: I perform vitrectomy prior to implantation

JR: We prefer doing vitrectomy after IOL implantation as it allows better stabilisation of the IOL in the bag

KKN: Before

59. How does polishing help? As it is the equatorial LECs which proliferate, right?

EW: I don't think it helps much unless I am removing something in the visual axis. Meticulous removal of cortex and equatorial lens epithelial cells is key.

RK: I do capsular polishing and polishing up till the equator by retracting the pupil. I guess this helps in many ways to prevent LEC proliferation and even glaucoma!! We need more evidence for this. It does not harm to do this anticipating the above-mentioned benefit.

YFC: I polish extensively up to the equator in all quadrants using Simcoe cannula

JR: Yes, polishing is immensely helpful in preventing the future development of a PCO or a soemmering ring in the future. Yes, it is the equatorial LECs which proliferate, so it is imperative to polish those completely

KKN: reduction of LECs reduces PCO, Phimosis and fibrosis of capsule

60. I have a 4-month old which I operated on at 4 weeks of age for bilateral cataract and was doing well on CL. She developed PCO, should I plan for AV and IOL implantation or would you continue on CL?

EW: At that age, I would remove the centre of the visual axis opacity but wait until older (age 3-5 years) for a secondary IOL.

RK: If she is doing well with CL, probably wait for the IOL. Can go ahead with just, the AV and membranectomy for now.

YFC: I would perform pars plana vitrectomy and if the CL compliance is good, continue with CL. However, if the aphakic correction is challenging, then I would consider secondary IOL either Artisan (iris fixated) or sulcus fixated depending on the parameters of the eye and the fellow eye

JR: IOL implantation should be considered only if the axial length is >17 mm and the corneal diameter is > 10 mm. If child and the parents are comfortable with contact lens, then it should be continued and IOL implantation can be done at later age to prevent development of myopic shift.

KKN: depends on size of eyes. If normal size and parents find CL difficult then implant. If parents happy with CLs then do AV but no IOL

61. How do you perform amblyopia treatment in bilateral and unilateral cataracts in the first 1 year and after?

EW: a good rule-of-thumb is to patch 1 hour per day per month of age to a maximum of half the waking hours.

RK: Begin with one hour per day to maximum of half the waking hours.

YFC: Aggressive alternate occlusion for bilateral and occlusion of the normal in unilateral. This is sometimes the most challenging aspect of paediatric cataract management

JR: Amblyopia treatment in bilateral cataract should be done 1:1 on both eyes as part time occlusion and in unilateral cataracts part time occlusion in the sound eye should be done

KKN: full cycloplegic refraction and prescribe for near, then patch better seeing eye. Remember if latent nystagmus present, patch better eye days per week NOT hours per day. with latent nystagmus, patching a few hours, only degrades vision; after 4 hrs. of continuous patching the latent component often dampens and that's when vision starts to improve

62. I've got a 1.5-year-old patient with IOL surgery done 4-months back. On 3rd follow up, he had post. synechiae and pupil failed to dilate even with atropine. Should I plan a synechiolysis now?

EW: I don't always reoperate just to break synechia – as long as the visual axis is clear.

RK: If the visual axis is clear, I would observe for now. If not, yes.

YFC: I would just observe if the visual axis is clear, no bombe, and IOP is normal. If it gets worse, then synechiolysis and pupiloplasty. Also remove any retained lens material which could be inciting the reaction. Post op I would treat more aggressively with steroids and mydiatics

JR: Yes, you can plan a synechiolysis with peripheral iridectomy and an anterior chamber wash with intracameral triamcinolone to prevent the future development of posterior synechiae

KKN: first figure out why this inflammation happened. Then do synechiolysis, but you may need to make pupil bigger surgically

63. Anybody using YAG capsulotomy in toddlers?

EW: no

RK: No

YFC: Yes. The youngest I have done was in 3 year olds without contact lens

JR: No, we are not using as the toddler will not cooperate

KKN: No

64. What about anisohyperopia and amblyopia?

EW: the anisohyperopia does not interfere with the amblyopia treatment if the glasses are worn well. In most cases, if the child will wear the patch, the child will wear the glasses.

YFC: See Above

JR: Amblyopia should be managed using part time occlusion. For anisohyperopia, contact lenses can be prescribed to prevent diplopia in case the difference between both eyes is more than 2.5 dioptries

KKN: see previous question about this

65. This rhexis overlay could be incorporated in any Zeiss microscope?

EW: I don't know but it is a good question to ask the Zeiss reps. I find it very helpful.

JR: The company needs to be contacted for such information

KKN: do not know

66. If u aim for target refraction more than +4 in infants, it would be amblyogenic?

EW: that is true. I weigh the advantages of emmetropia later with the anticipated compliance for glasses. Amazingly, the uncorrected +4 is not as amblyogenic as you would think. There is much better vision with an IOL and uncorrected

hyperopia than would be predicted – it may be pseudo-accommodation. The bottom-line is that glasses and patching are both needed if hyperopia is left. Naturally, if you think that there is no way that the glasses will work then don't leave hyperopia.

RK: Yes. It is, so glasses should be used. This is much better than not wearing any optical correction at all.

YFC: Yes, certainly. Especially if compliance to optical correction is poor. See above for further comments

JR: Yes, it can be amblyogenic. The aim should be moderate hyperopia

KKN: yes, but easier to correct with glasses and that refraction often changes rapidly to being emmetropic or myopic

67. At what age are majority of you implanting IOLs?

EW: above the age of 7 months.

RK: Case to case basis. Please see my answer to Q 1

YFC: See above

JR: We are implanting IOL's when axial length >17 mm and corneal diameter is >10 mm

KKN: see previous question about this

68. In Singapore, where the myopia prevalence is very high, I tend to do much less undercorrection. What about the rest in countries with high myopia rates?

EW: At least you have high compliance with glasses after surgery.

RK: Yes, that is one of the options.

YFC: I have a similar view. I worry less about adult myopia as there are many excellent corrective options e.g. ICL implant, LASIK, etc.

JR: We have a moderate prevalence of myopia in India. We undercorrect by 20% up to 2 years of age and 10% between 2 - 8 years of age.

KKN: we don't see that much myopia

69. Any comments on performing a posterior capsulotomy intraoperatively, in order to prevent future PCOs (seen commonly)?

EW: I much prefer to do a primary posterior capsulotomy. Children may not cooperate with the YAG laser and higher than normal energy may be needed. Avoiding frequent YAG laser by doing primary PCCC is a good idea. It is another personal preference for each surgeon to decide on.

RK: I prefer to do primary posterior capsulotomy and AV.

YFC: See above

JR: Yes, we are doing it routinely for children less than 8 years of age

KKN: I do PPC and anterior vitrectomy in everyone under 5 yrs. and I do PPC in everyone until 17 yrs. old

70. If you anticipate a IOL exchange, would you consider sulcus implant?

EW: sulcus implants are much easier to exchange.

RK: Either ways, it is fine. Sulcus fixated IOL is easier to exchange.

YFC: I prefer phakic ICL for high myopia / astigmatism correction in a pseudophakic eye and sulcus 3 piece IOL implant for hyperopic correction in aphakic eye if the capsule remnant is still intact. I have also used Artisan iris fixated IOL. IOL exchange is generally more difficult and hazardous so I avoid it

JR: We would first aim for an in-the-bag IOL implantation and if that is not possible due to inadequate posterior capsular support, we would implant it in the sulcus with IOL power modification

KKN: Have never implanted expecting to exchange, so cannot advise

71. Do you still use hydrophilic acrylic in infants and children? Especially in India?

EW: I can't answer for India, but in the USA the only hydrophilic acrylic I have, is the Rayner C-flex and it does well in children. Not all hydrophilic acrylics are good though.

RK: No, we don't use. Please see this publication where hydrophilic IOLs are used. Best to avoid them. Pehera NK, Bojja S, Vemuganti GK, et al. Opacification of intraocular lenses implanted during infancy: a clinicopathologic study of 4 explanted intraocular lenses. *Ophthalmology*. 2011;118(11):2128-2132.e1.

YFC: Hydrophobic IOL only

JR: No we are not using it in our institutional practice in India

KKN: I only use hydrophobic acrylic

72. What is the overall diameter of the Rayner?

EW: 5.76 or 6 mm optic – overall is 12 mm (I think)

RK: I do not have experience with this.

JR: Overall diameter of Rayner lens is 12.5 mm

KKN: not sure

73. Anyone does a pars plicata lensectomy (without implantation) using the vitrector?

EW: no, I do my no-IOL lensectomy from anterior through two small paracenteses.

RK: No

YFC: Used to do in the distance past

JR: We do a limbal based vitrectomy being anterior segment surgeons.

KKN: No

74. What does everyone use for secondary IOL implantation?

EW: Most of my secondary IOL implantations are in-the-bag after reopening the capsular remnant and removing any Soemmering ring. For secondary IOL in-the-bag, I use a single-piece hydrophobic IOL. If reopening the capsular remnant is not possible then I use a 3-piece acrylic (posterior angulated) IOL or the Rayner C-flex.

RK: Single piece IOL for in the bag which I always attempt, if sulcus fixated, I use 3 piece IOL. Always important to remove the Soemmerring ring 360 degrees.

YFC: As above

JR: We prefer using a hydrophobic three-piece foldable acrylic IOL for secondary IOL implantation

KKN: MA60AC IOL

75. When the anterior and posterior capsules stick, are you trying to separate them when you implant an IOL? Or do you suggest implanting it directly in the sulcus?

EW: If there is a Soemmering ring, then I separate the capsules and clean out the ring. If not, then sulcus implantation is fine.

RK: Yes, I try to separate always and if there is adequate space I implant a single piece IOL.

YFC: (Most separation can be done successfully. Importantly, vitrectomy must be adequately performed as the “sticking together” is sometimes due to prolapsing vitreous or vitreous wick to the wound. I always prefer to implant in the capsular bag. If “separation” is not possible, sulcus implantation with 3 piece IOI with optic capture can be considered

JR: We try opening the anterior and posterior capsules, but if they do not open up, we place the IOL in sulcus

KKN: open the bag after doing posterior rhexis; this should prevent anterior and posterior capsules from sticking again

76. Do you perform angle examination routinely in paediatric cataract cases? Does cataract morphology matter in terms of glaucoma risk?

EW: Glaucoma risk is higher in micro-cornea and with very early surgery. An angle examination is a good idea but the angle structures are immature and may be hard to interpret.

RK: Yes, I do in all infants. Morphology of cataract may not be a separate risk factor.

YFC: Please refer to the previous Paediatric cataract webinar

JR: No we do not routinely perform angle examination in paediatric cataract cases. However, if IOP is high and disc changes are obvious, we refer them to the glaucoma specialists.

KKN: yes, I do. Cataract morphology is not that critical in terms of glaucoma risk

77. While doing pars plana vitrectomy do you use triamcinolone?

EW: no

YFC: see above

JR: We use triamcinolone while doing anterior vitrectomy

KKN: No