

# Case of a 9 Year Old Child With A Corneal Cut

SAVERIO LUCCARELLI, MD

MATTEO SACCHI, MD

San Giuseppe Hospital

Milan, Italy

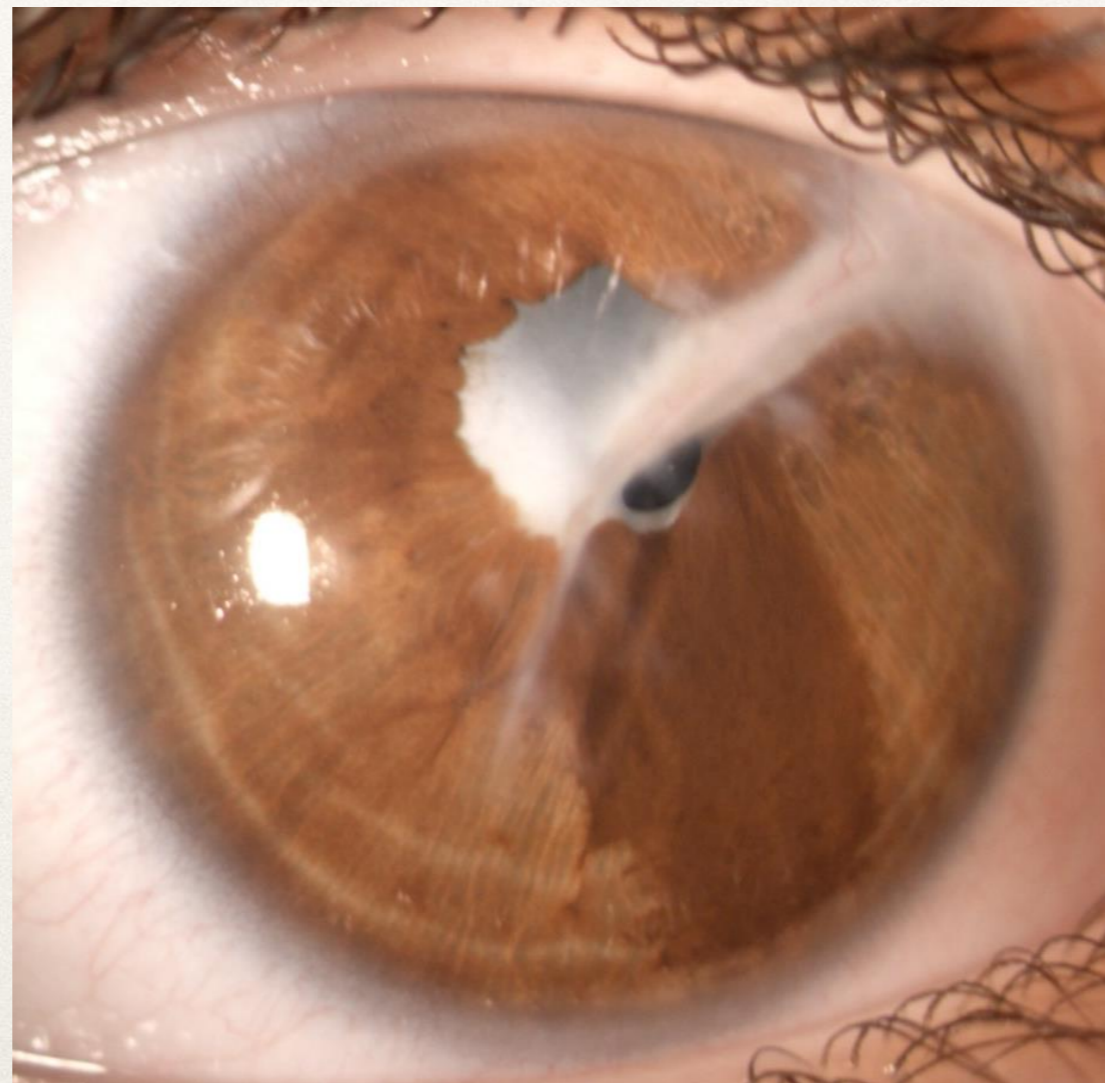


Università degli  
studi di Milano



University  
Eye Clinic  
San Giuseppe

- 9-year-old male
- 4 months ago, had a repair of a sclero-corneal penetrating trauma with expulsion of the crystalline lens
- First surgery performed immediately after trauma in the country of origin with Sclero-corneal suture.
- Suture partially removed 2 months after the trauma



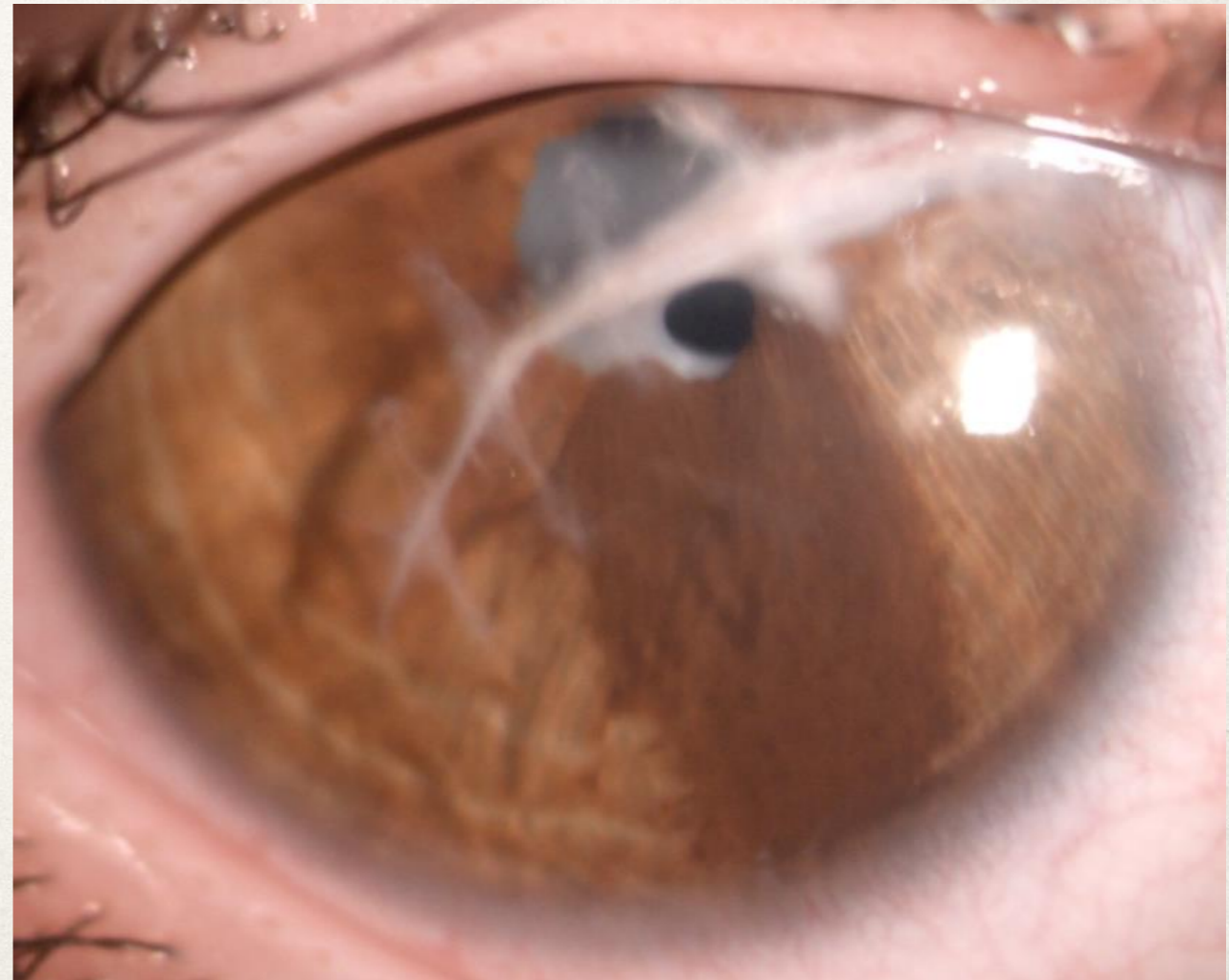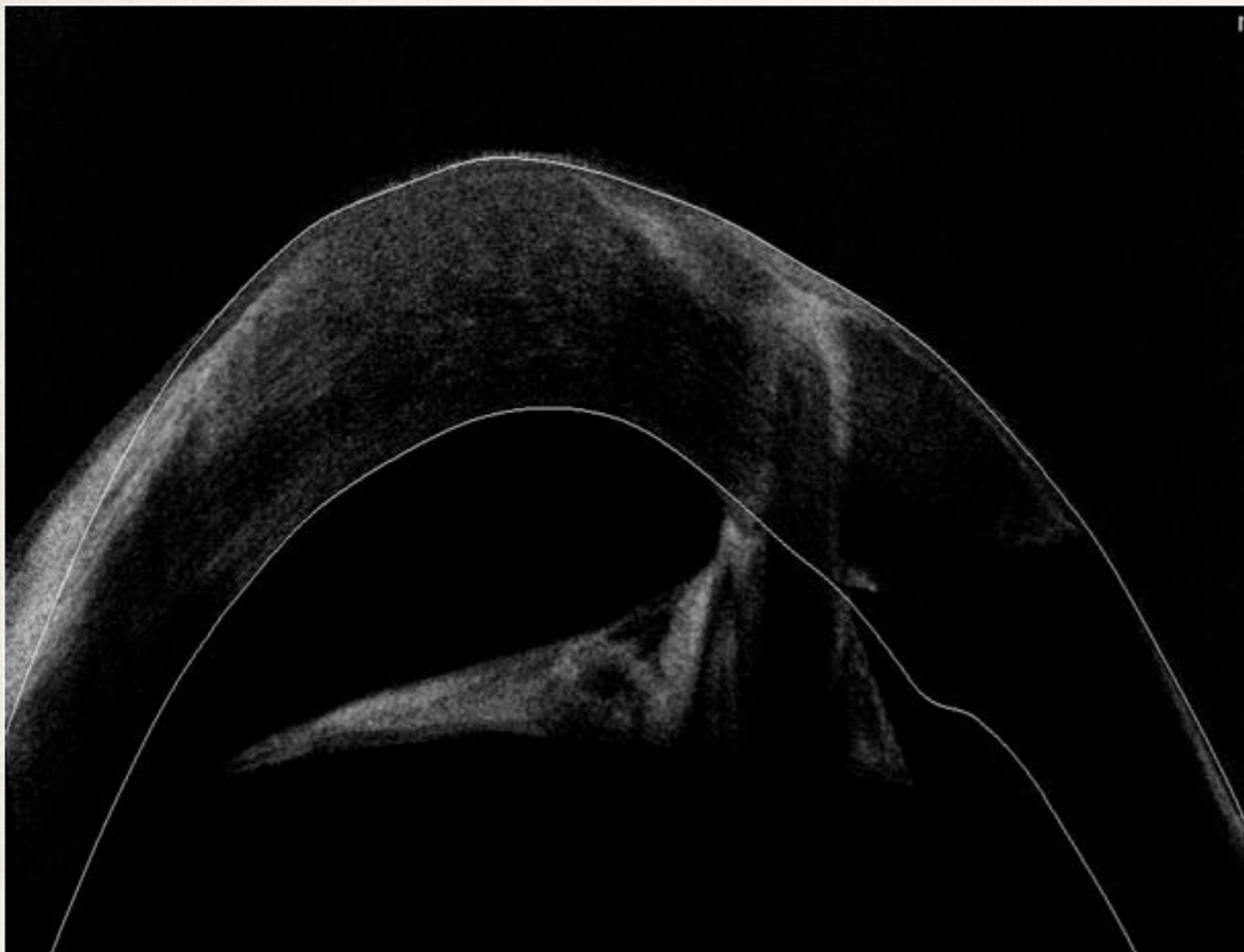ODV: hand movements

CT: exotropia

ODSA: corneal vascularized scar from the 2 o'clock to 7 o'clock position, anterior synechiae with iris scar from the limbus to the pupil at the 2 o'clock position, thick pupillary membrane, corectopia, aphakia

ODT: digit +

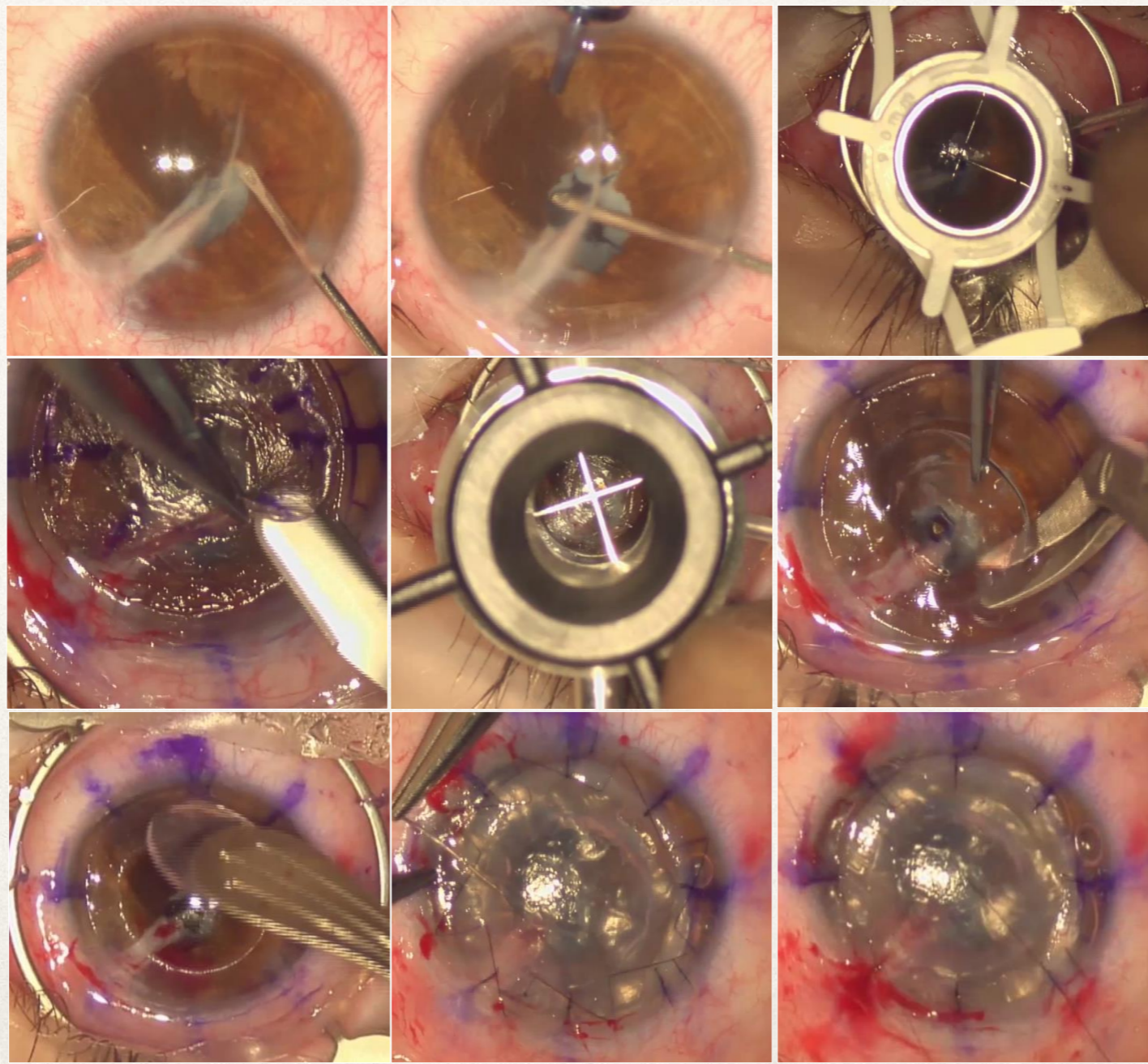
ODF: ECO B-SCAN: no vitreal nor retinal alteration.



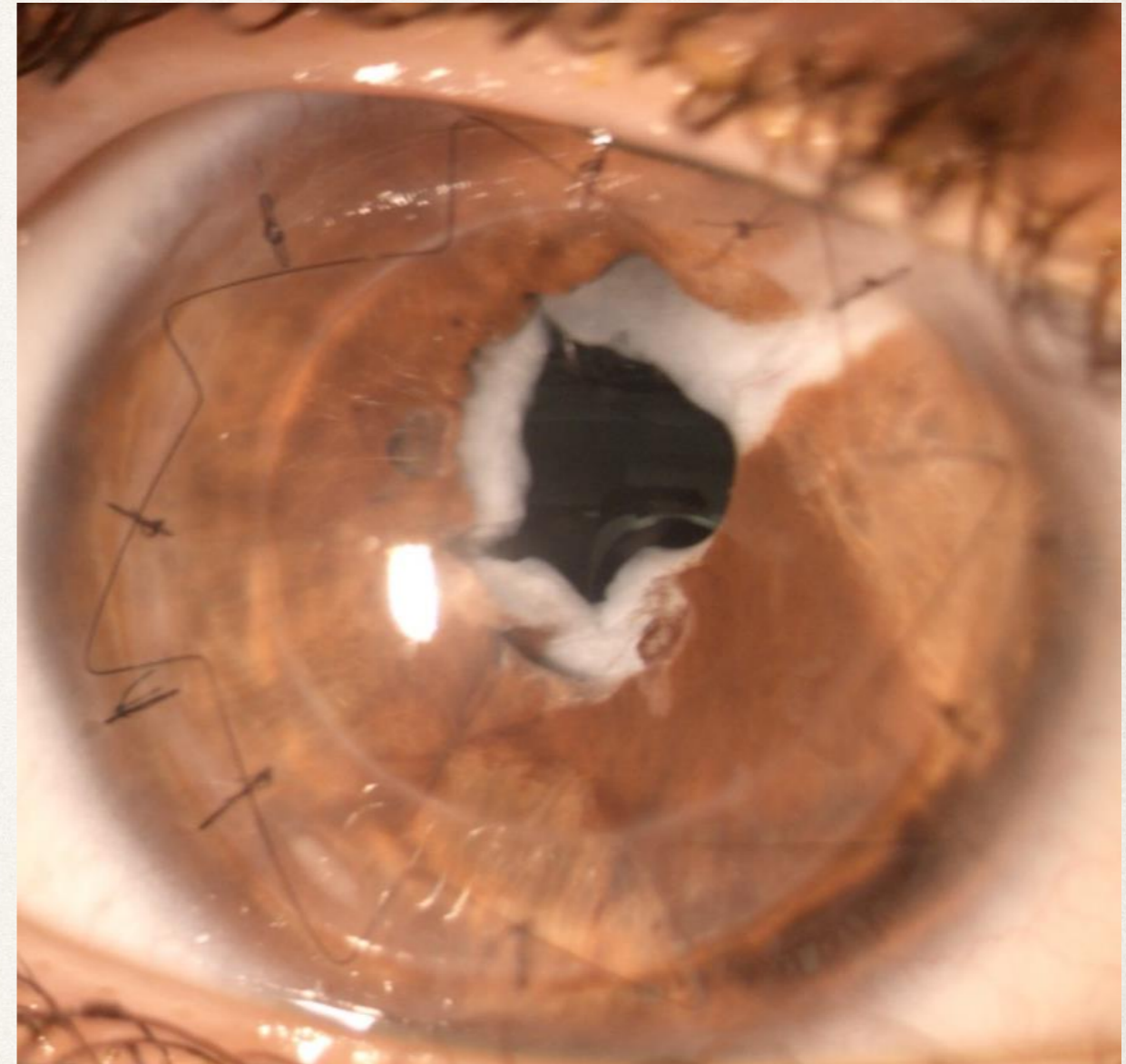
A pupilloplasty with membranectomy was performed combined with a Mushroom Penetrating Keratoplasty, using a pre-cut (microkeratome) donor corneal graft at the depth of 250 microns with a microkeratome.

The Hat was punched at 9,00mm and the Stem at 6,50mm.

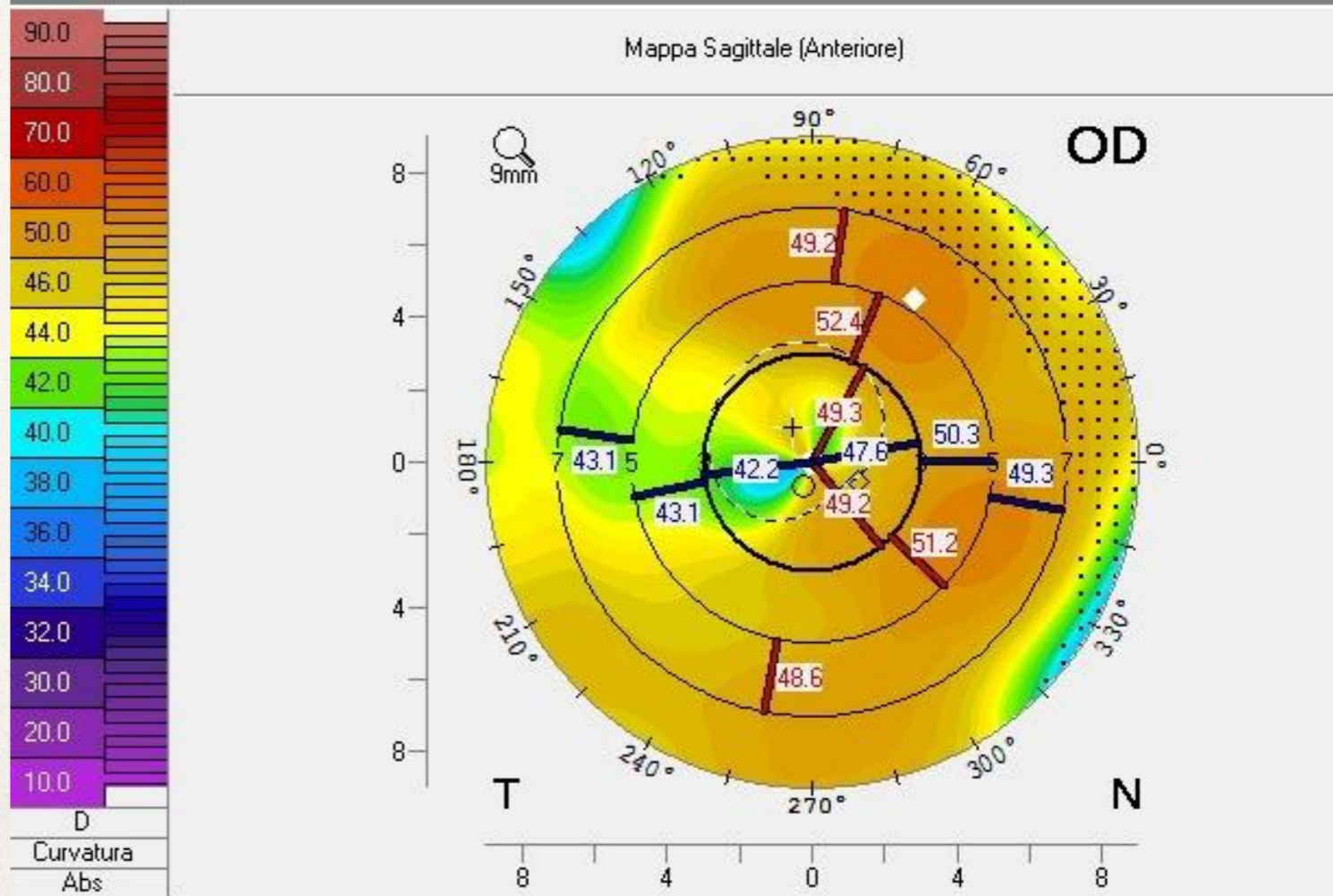
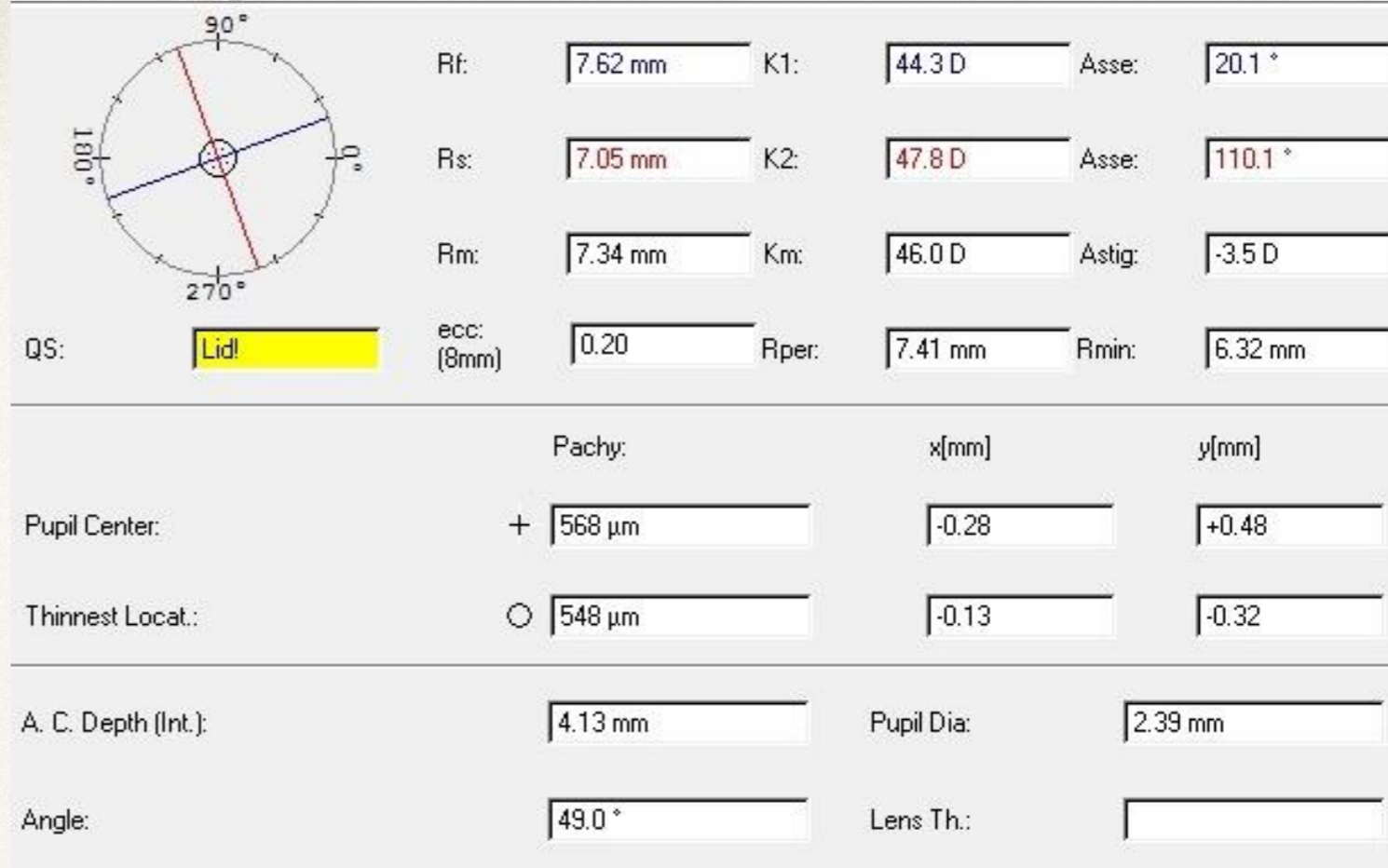
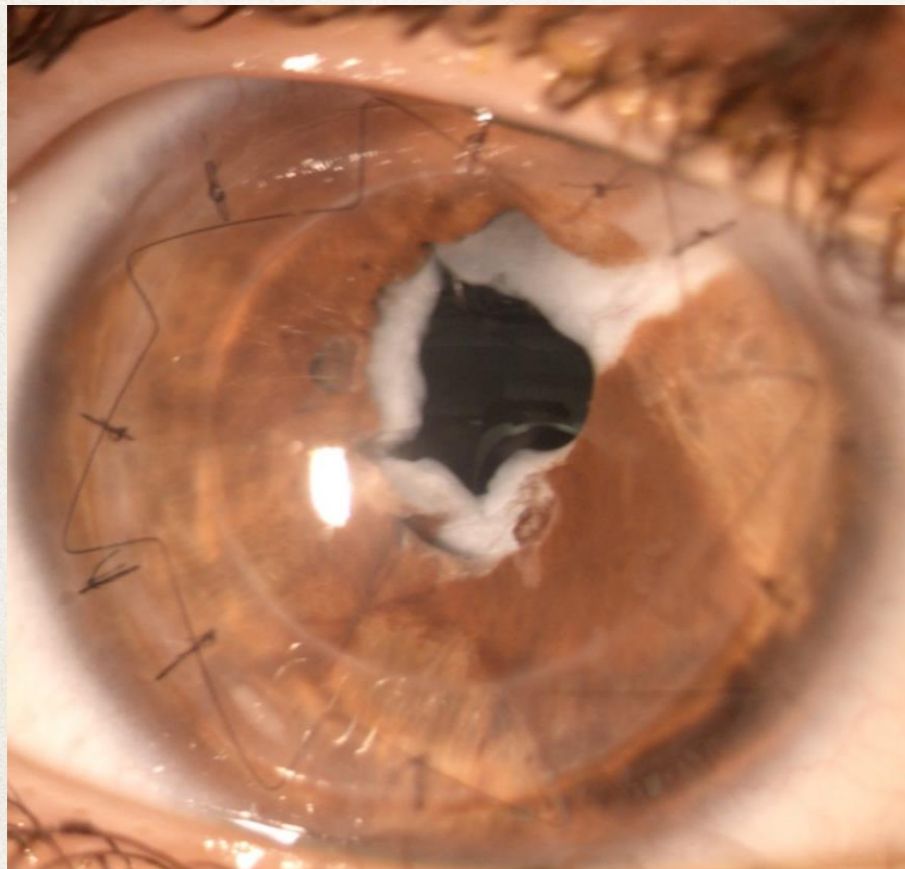
**MEDICATION:** Topical antibiotics and steroids, every 2 hours the first week , then tapered to b.i.d. at 2 months post surgery.



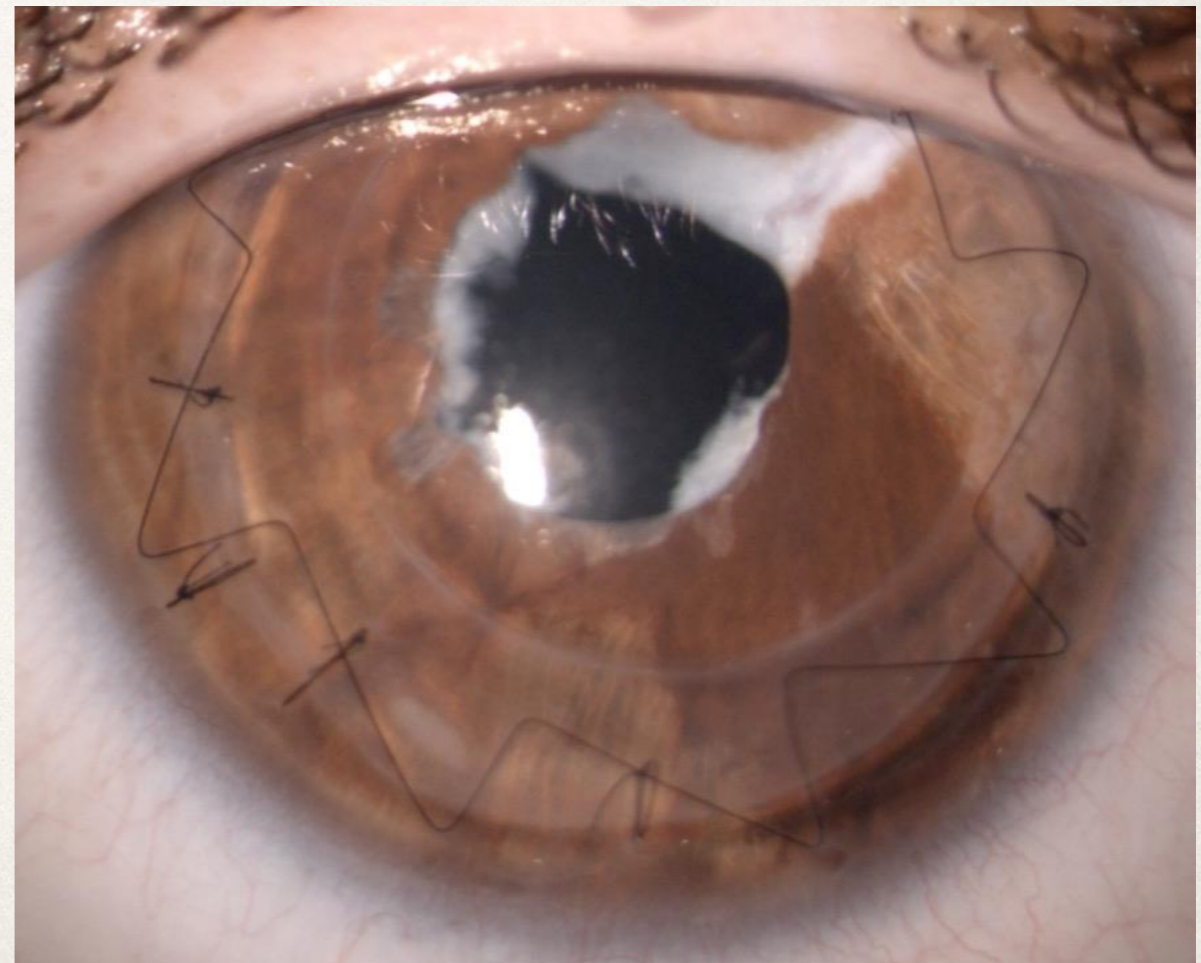

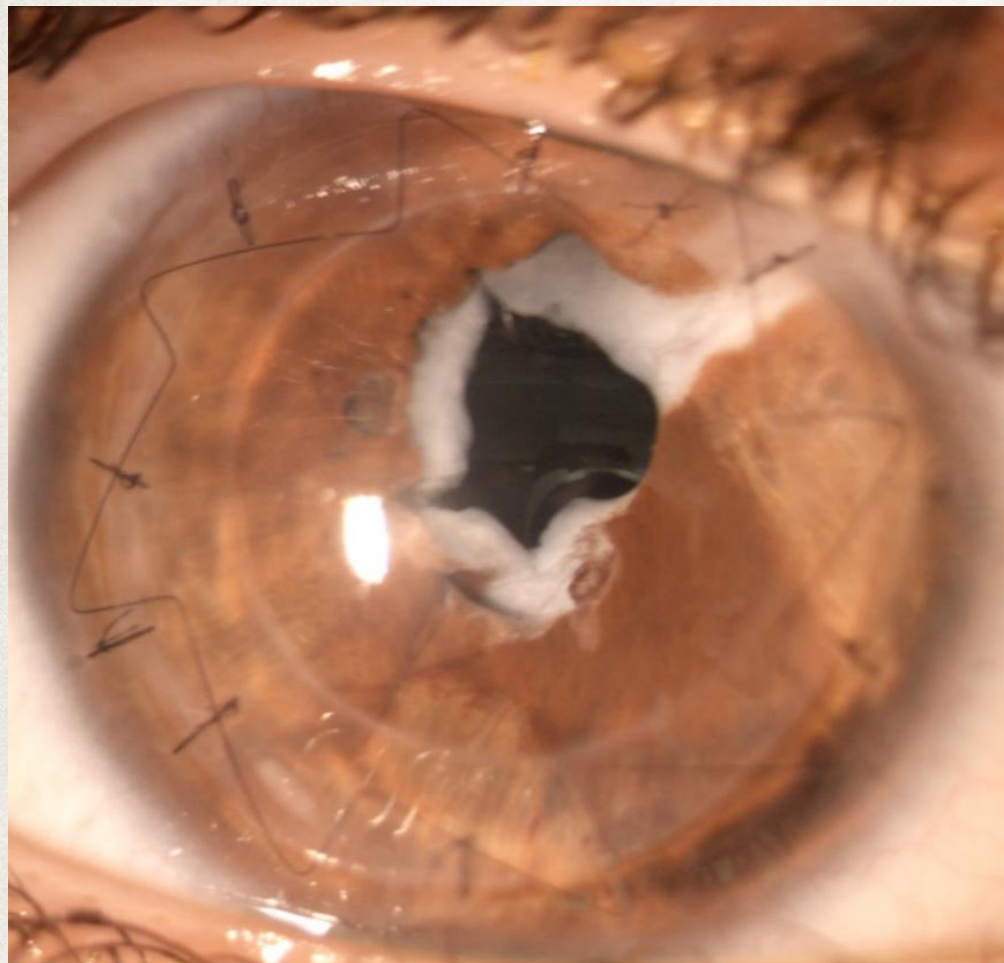
- 2 months post-op cornea was healed and sutures were completely covered by epithelium
- BCVA was 0.05 with +12.00 D sf,
- IOP = 14 mm hg
- MEDICATION:                   steroids tapered to b.i.d.



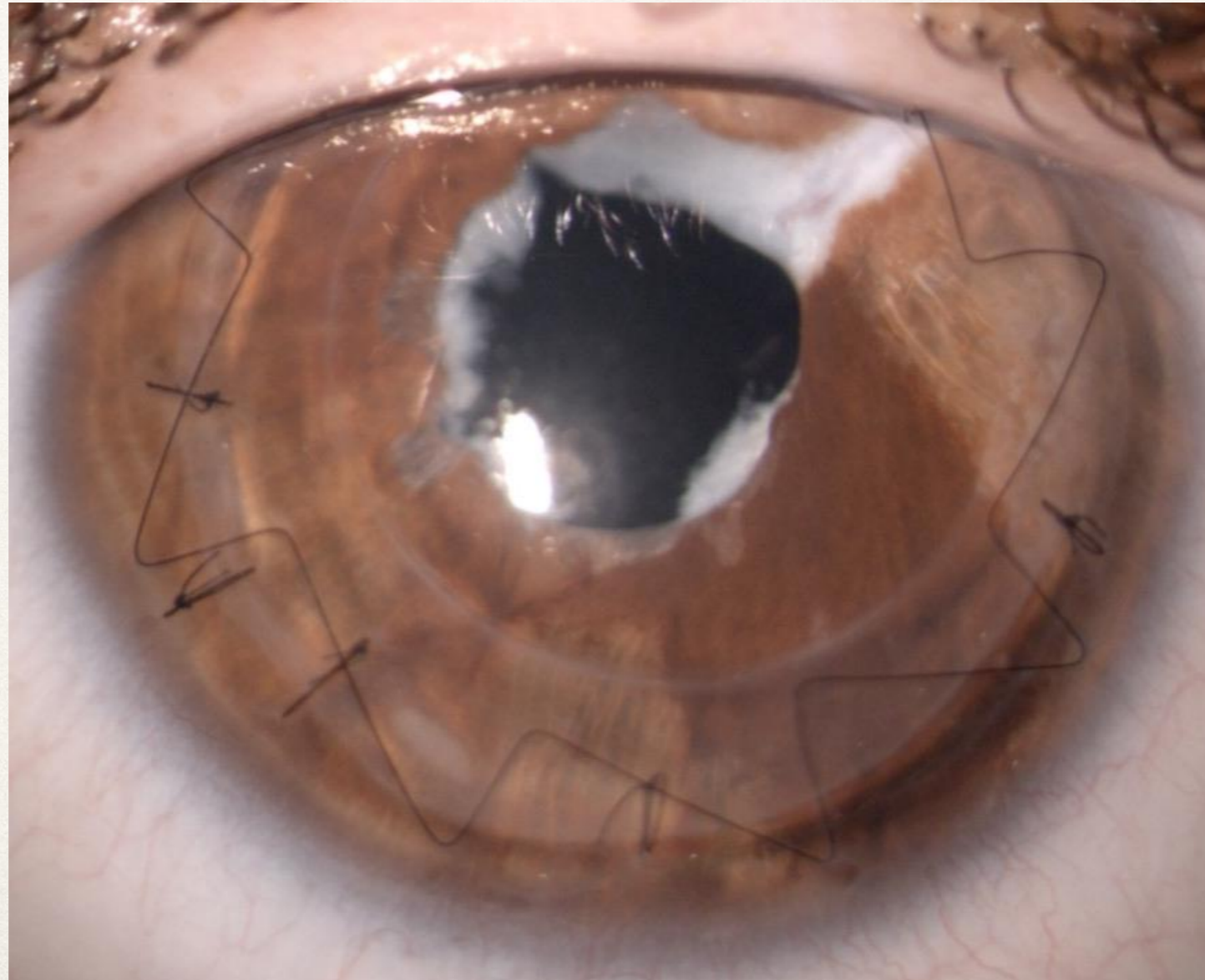
- 2 months post-op, cornea was healed and sutures were completely covered by epithelium
- A medium (-3.50 D) and slightly irregular astigmatism was present
- A first attempt of correction with RGP Lens was performed and BCVA was 0.1



- 3 months post-op, a YAG laser pupillary membranotomy was performed to achieve a well centered and dilated pupil



- After the YAG laser pupillary membranotomy, a hybrid contact lens fit was prescribed to enhance the comfort
- At 5 months follow-up, the BCVA was 0.3 and exotropia became intermittent
- At 6 months FU the BCVA was 0.5 and exotropia disappeared
- MEDICATION: Topical steroid, 1 drop daily



## Some questions about future challenges :

1) Could a secondary IOL implant be a choice for the future?

a) Yes

b) No; Maintain correction with well tolerated Hybrid CL

2) Supposing a secondary IOL implant is preferred, when would it be preferable?

a) Following astigmatism stabilization after suture removal?

b) Later / Other?

3) Which surgical IOL solution would you prefer?

a) Iris fixated IOL

b) Scleral fixated IOL

c) Angle fixated IOL

**Could our Experts please answer the following questions in addition to answering the questions on the previous slide?**

- 1) Supposing a secondary IOL implant is preferred; there is a possibility of irregular astigmatism. What other options can you suggest as an alternative to CL ?
- 2) Do you think it is important to correct near vision? If so, how ?
- 3) Do you agree with the surgical choice of the Mushroom PK ?

*Thank You*

---