

WWW 9 – Season 2 – Uveitis



Marie Hélène Errera



Somasheila Murthy



Virginia Utz



Ken K. Nischal



Sanna Leinonen



Nisha Acharya



Virginia Utz (VMU), Marie Hélène Errera (MHE), Sanna Leinonen (SL),
Ken K. Nischal (KKN), Nisha Acharya (NA), Somasheila Murthy (SM)

1. What adalimumab suspension schedule is used in patients without inflammation for at least 6 months?

VMU: I am not sure what the questions is asking, so please feel free to clarify further if I do not answer your question fully. In a patient on adalimumab with quiescent disease x 6 months, we would continue for at least 2 years per the both the American College of Rheumatology (USA) and SHARE initiative (Europe). Tapering topical steroids should be considered before reducing biologic and non-biologic DMARDs per the ACR recommendations. However, evidence for this practice is limited at best. Currently, an ongoing, international multi-centre trial is exploring which patients with JIA-associated uveitis should continue adalimumab versus those who are at low risk for recurrence and can safely stop the medication. This study is called the ADJUST Trial (<https://clinicaltrials.gov/ct2/show/NCT03816397>). (information below as well as information for patients).

SHARE Initiative: Constantin T, et al., Ann Rheum Dis 2018;1-11:

Table 2 Recommendations for disease activity measurement in juvenile idiopathic arthritis (JIA)-related uveitis				
	L	S	Agreement (%)	References
4. There should be good communication between the ophthalmologist and the paediatric rheumatologist concerning changes in disease activity treatment changes and responsibility for treatment monitoring.	3	C	100	71
5. There is a need to develop shared outcome measures to help guide decisions on systemic treatment.	4	D	100	
6. At present, there is no validated biomarker to follow the activity of uveitis.	2A	B	100	4 21 29 31 32 37 41 46 72–76
7. At present, no widely accepted definition of inactive disease for JIA-related uveitis is available. The goal of treating JIA-associated uveitis should be no cells in the anterior chamber. The presence of macular and/or disk oedema, ocular hypotony and rubeosis iridis may require anti-inflammatory treatment even in the absence of AC cells.	2B	B	100	4 69 78
8. We recommend 2 years of inactive disease off topical steroids before reducing systemic immunosuppression (both DMARDs and biological therapies).	3	C	92	67

Agreement indicates the % of experts that agreed on the recommendation during the final voting round of the consensus meeting.

1A, meta-analysis of cohort studies; 1B, meta-analysis of case-control studies; 2A, cohort studies; 2B, case-control studies; 3, non-comparative descriptive studies; 4, expert opinion; A, based on level 1 evidence; B, based on level 2 or extrapolated from level 1; C, based on level 3 or extrapolated from level 1 or 2; D, based on level 4 or extrapolated from level 3 or 4 expert opinion. DMARD, disease-modifying anti rheumatic drugs; L, level of evidence; S, strength of evidence.

Constantin T, et al. Ann Rheum Dis 2018;0:1–11. doi:10.1136/annrheumdis-2018-213131

3

ACR: Angeles-Han S, et al., Arthritis Care & Research, 2019, 71 (6), 703-716.

Table 3. (Cont'd)

Recommendation	
Recommendations for tapering therapy for uveitis	
In children and adolescents with JIA and CAU that is controlled on systemic therapy but remain on 1–2 drops/day of prednisolone acetate 1% (or equivalent):	
→	• Tapering topical glucocorticoids first is strongly recommended over systemic therapy (Recommendation 18, PICO 6).
In children and adolescents with JIA and uveitis that is well controlled on DMARD and biologic systemic therapy only:	
→	• Conditionally recommend that there be at least 2 years of well-controlled disease before tapering therapy (Recommendation 19, PICO 29).

* Each recommendation had very low quality level of evidence. JIA = juvenile idiopathic arthritis; PICO = Patient/Population, Intervention, Comparison, and Outcomes; CAU = chronic anterior uveitis; DMARDs = disease-modifying antirheumatic drugs; TNFi = tumor necrosis factor inhibitor; AAU = acute anterior uveitis.

† High-risk children are those with oligoarthritis, polyarthritis (rheumatoid factor negative), psoriatic arthritis, or undifferentiated arthritis who are also antinuclear antibody positive, younger than 7 years of age at JIA onset, and have JIA duration of 4 years or less.

‡ Definition of new CAU activity: no prior uveitis or loss of control of previously controlled uveitis.

Australia/New Zealand:

Smith JR, Matthews JM, Conrad D, Hall AJ, Niederer RL, Singh-Grewal D, Tay-Kearney ML, Wells JM, Zagora SL; Australian and New Zealand Juvenile Idiopathic Arthritis-Uveitis Working Group, McCluskey PJ. Recommendations for the management of childhood juvenile idiopathic arthritis-type chronic anterior uveitis. Clin Exp Ophthalmol. 2021 Jan 10. doi: 10.1111/ceo.13856. Epub ahead of print. PMID: 33426782.

Full references available:

1. American College of Rheumatology (ACR) / Arthritis Foundation Guideline for the Screening, Monitoring, and Treatment of Juvenile Idiopathic Arthritis-Associated Uveitis.

- Applies to JIA-uveitis (or by extension idiopathic JIA-like, chronic anterior uveitis)

- Reference: Angeles-Han ST, Arthritis Care & Research, 2019, 71 (6), 703-716.

- Full text link: <https://onlinelibrary.wiley.com/doi/full/10.1002/acr.23871>

2. Consensus-based recommendations for the management of uveitis associated with juvenile idiopathic arthritis: The SHARE (The Single Hub and Access point for pediatric Rheumatology in Europe) Initiative.

-Overlapping features with ACR guidelines above, some differences

- Reference: Constantin et al., Ann Rheum Dis 2018; 77 (8); 1107-1117.

- Full text link: <https://www.ncbi.nlm.nih.gov/pmc/articles/PMC6059050/>

3. Acharya NR, Ebert CD, Kelly NK, Porco TC, Ramanan AV, Arnold BF; ADJUST Research Group. Discontinuing adalimumab in patients with controlled juvenile idiopathic arthritis-associated uveitis (ADJUST-Adalimumab in Juvenile Idiopathic Arthritis-associated Uveitis Stopping Trial): study protocol for a randomised controlled trial. Trials. 2020 Oct 27;21(1):887. doi: 10.1186/s13063-020-04796-z. PMID: 33109240; PMCID: PMC7590716.

Full text available: <https://www.ncbi.nlm.nih.gov/pmc/articles/PMC7590716/>

Patient information on trial:

<http://www.oliviasvision.org/research-medical-trials/stopping-adalimumab/>

<https://aapos.org/patients/patient-resources/pediatric-uveitis/adalimumab-in-juvenile-idiopathic-arthritis-associated-uveitis-stopping-trial-adjust>

SL: Adalimumab should NOT be discontinued as soon as 6 months after achieving remission.

a) If remission is achieved, taper both systemic and topical steroids to 0 if SUN 0 can be maintained with steroids.

b) If remission is achieved, wait for at least 2 years without reducing the antirheumatic treatment. Check the SHARE Initiative.

c) After two years of remission, you can consider reducing antirheumatics in patients who are not at high-risk of vision loss i.e., patients without ocular complications and without a high-grade of inflammation before the start of adalimumab. I recommend against discontinuing adalimumab in patients who have had a complicated course of uveitis. If you discontinue adalimumab, I recommend against tapering. I recommend continuing DMARD medication such as methotrexate after you have discontinued adalimumab and check the patient every 6-8 weeks.

Constantin T et al. Consensus-based recommendations for the management of uveitis associated with juvenile idiopathic arthritis: the SHARE initiative. Ann Rheum Dis. 2018 Aug;77(8):1107-1117. doi: 10.1136/annrheumdis-2018-213131.

KKN: I have always relied totally on my rheumatology colleagues to help me with this. I think if there is an opportunity to develop a multi-disciplinary team for uveitis, then the ophthalmologist should do that.

NA: I agree with the above. We recommend 2 years of remission prior to attempting to stop therapy. Close monitoring (every 1-2 months) is needed when trying to stop given the risk of recurrence and because the uveitis is asymptomatic.

SM: Pretty much the same as all have mentioned, however due to the cost of Adalumimab we tend to stop the infusions after one year of quiescence and maintain on oral therapy, typically Methotrexate for several years with monitoring.

2. Does an intraocular steroid implant (ozurdex) play a role in "unresponsive" cases where compliance with topical meds may be an issue?

VMU: While augmentation of systemic, steroid-sparing therapy is preferred, cases exist where Ozurdex may be helpful, especially when complications such as CME are concurrent. However, it is important to select candidates, preferably a patient without steroid-response to topicals (which may be hard to determine if the patient is non-adherent to topicals). The IOP must be monitored closely in this setting.

[Fluocinolone acetonide intravitreal implant \(Retisert®\) in the treatment of sight threatening macular oedema of juvenile idiopathic arthritis-related uveitis.](#)

References: Leinonen S, Immonen I, Kotaniemi K. *Acta Ophthalmol.* 2018 Sep;96(6):648-651. doi: 10.1111/aos.13744. Epub 2018 Apr 14. PMID: 29655222

Ansari AS, Amir Z, Williams GS. Bilateral 0.19 mg Fluocinolone Acetonide Intravitreal Implant in the Successful Treatment of Juvenile Idiopathic Arthritis-Associated Uveitis and Secondary Macular Oedema: A Case Report and Review of Intravitreal Therapies. *Ophthalmol Ther.* 2021 Jan 19. doi: 10.1007/s40123-020-00328-9. Epub ahead of print. PMID: 33464558.

SL: Ozurdex implantation is too short-acting in the treatment of JIA-uveitis. If you have to, you can use it as a bridging treatment while you wait for the antirheumatics to work. I would consider Ozurdex for an acute macular oedema as a bridging treatment before antirheumatics work.

Pichi et al. Sustained-release dexamethasone intravitreal implant in juvenile idiopathic arthritis related uveitis. *Int Ophthalmol* 2017.

KKN: I have never used an intraocular steroid implant. Even in cases of non-infectious related Uveitic CME I have not found the need.

NA: Local steroid injections/implants can be useful as adjunctive therapy for CME or refractory vascular leakage. The issue is that they are short-acting so not ideal for a chronic illness. However, they can be an option for selected patients.

SM: It is not to be used as a stand-alone therapy, but in conjunction with other therapy as mentioned above, and in some recalcitrant cases there is a utility. It has a rapid onset of action and in cases with severe CMEs I find it helps to get control till the other agents can work. However it has a pretty short duration, not even the 6 months that is presumed.

3. Does anybody have seen severe anterior uveitis associated with COVID recently ?

VMU: We have not observed as part of either the acute infection or associated with MIS-C. However, the children with MIS-C are so very ill (usually in the ICU with a macrophage-activation type syndrome), we do not see them at the slit lamp until they are already on high-dose corticosteroids. They have usually also received other immunomodulator medications. There was one report in the adult literature of an adult patient with uveitis as part of MIS-C. Link to text as follows: <https://www.ncbi.nlm.nih.gov/pmc/articles/PMC7361787/pdf/JMV-9999-na.pdf>

MHE: No, I have not

SL: No

KKN: No

NA: There are few cases that have been described on the American Uveitis Society listserv. There are presumptive cases where a patient had COVID and there was no other identifiable cause of the uveitis.

SM: No

4. How safe is intraocular steroid implant in children?

VMU: Limited experience, will defer to my colleagues. Candidate-selection is important.

SL: Not as safe as in adults.

Triamcinolone: IOP rise is seen in 31%, cataract progression in 55%.

Sallam et al. Short-term safety and efficacy of intravitreal triamcinolone acetonide for uveitic macular edema in children. Arch Ophthalmol. 2008;126(2):200. doi:10.1001/archophthalmol.2007.59

Dexamethasone implants: Mean IOP rises 10mmHg, cataract progression in 66%, cataract surgery in 25% Sella R et al. Dexamethasone intravitreal implant (Ozurdex®) for pediatric uveitis. Graefes Arch Clin Exp Ophthalmol. 2015;253(10):1777-1782.

Fluocinolone implantation (Retisert, not available commercially): IOP rise 6/8, IOP surgery 4/8, cataract surgery in 100%. Leinonen et al. Fluocinolone acetonide intravitreal implant (Retisert®) in the treatment of sight threatening macular edema of juvenile idiopathic arthritis-related uveitis. Acta Ophthalmol. 2018;96(6):648-651.

Other fluocinolone implants: Not studied.

KKN: I have never used it

NA: They work well for uveitis but the glaucoma and cataract issues make them suboptimal for children. However, we sometimes do need them for refractory macular edema or vasculitis if systemic therapy is not sufficient. If a patient is pseudophakic and has no IOP issues (or has had glaucoma surgery), a long-acting implant may be an option.

SM: The only intra-ocular steroid we have limited experience with is Ozurdex, however it does have a propensity for IOP rise and cataract just as in adults and needs monitoring. Most of the published reports are on short case series and have reported both cataract progression or raised IOP.

5. In hypertensive uveitis without inflammation but without response to treatment with drainage devices, what other therapeutic alternative do we have?

VMU: Goniotomy or trabeculotomy could be considered if angle open.

Bohnsack BL, Freedman SF. Surgical outcomes in childhood uveitic glaucoma. Am J Ophthalmol. 2013 Jan;155(1):134-42. doi: 10.1016/j.ajo.2012.07.008. Epub 2012 Oct 2. PMID: 23036573.

SL: If the patient is on steroids, taper the steroids.

Trabeculectomy or goniotomy can be considered as a primary glaucoma surgery before a drainage device is implanted. If a drainage device surgery has already been performed in the eye and the patient is on topical IOP-lowering medication and the IOP is still high, you may consider a piggyback drainage. A piggyback is an additional plate and shunt added to the previously inserted plate.

Välimäki J. Insertion of sequential glaucoma drainage implant in a piggyback manner. Eye (Lond). 2015 Oct;29(10):1329-34.

KKN: depending on the cause and depending on the angle appearance : If the angle appearance shows a membrane (uveitic) goniotomy is worth doing. If the cause is NOT chronic JIA related uveitis then I have done trabeculectomy with MMC in about 6 cases in my career.

SM: Based on the etiology, for example viral uveitis would have secondary glaucoma but very minimal inflammation and needs therapy with antivirals. Steroid response could also be the cause of the raised IOP. For the glaucoma management, I defer the decision to my glaucoma colleagues

6. After stopping methotrexate, how often does one screen the patient?

VMU: In a patient with JIA and without uveitis, 3 months after discontinuing the MTX and then follow screening guidelines based on JIA risk factors.

In a child with a diagnosis of uveitis who has discontinued MTX, I usually see at 6-8 weeks.

SL: JIA-patients with history of uveitis: Every 6-8 weeks until 8-9 months and then more infrequently. JIA-patients without uveitis: At 3 months after the discontinuation of methotrexate. After which you can follow the local screening guideline.

Kalinina Ayuso V et al. Relapse rate of uveitis post-methotrexate treatment in juvenile idiopathic arthritis. Am J Ophthalmol. 2011 Feb;151(2):217-22. doi: 10.1016/j.ajo.2010.08.021.

KKN: Either 4-6 weekly (with uveitis) or 3 monthly (no uveitis)

NA: Agree with above

SM: Same as above

7. Does intracameral steroid depot has any role in anterior uveitis in children

VMU: This is not an approach that we use, will defer to my colleagues to respond.

SL: Their role has been studied in cataract surgery related to other causes than uveitis. To my understanding there are no studies on intracameral use of steroids in pediatric uveitis and I have not used intracameral steroids in anterior uveitis.

Mohamed TA. Effect of intracameral triamcinolone acetonide on postoperative intraocular inflammation in pediatric traumatic cataract. Eur J Ophthalmol. 2016 Mar-Apr;26(2):114-7. doi: 10.5301/ejo.5000648.

KKN: I use intracameral dexamethasone after cataract surgery but never for uveitis

NA: I do not use this for anterior uveitis.

SM: Same as KKN, use is at the end of the cataract surgery in uveitis, but not for regular management of the inflammation

8. I wonder when would you start to try to withdraw patient from Adalimumab, after how long (2 years minimum treatment? or?)

VMU: 2 years or more. Unfortunately, the disease tends to come back in so many usually, around 180 days after the medication is tapered. Dr. Acharya is addressing this specific question in an international multicenter control trial. (Please see references used in Question #1).

SL: See questions 1, 11. I refrain from discontinuing adalimumab during childhood in patients who have a complicated course of uveitis, history of macular oedema, intraocular operations, glaucoma – patients who are at high risk of vision loss. You can expect a high-grade relapse with additional complications at around 6 months after the discontinuation.

KKN : Only done in conjunction with my rheumatology colleague

NA: Please see question #1.

SM: Same as above

9. Is JIA common in Asian countries. We don't see many cases in Africa. Might genetics have a role to play?

VMU: Absolutely. Although JIA is not a monogenic disorder, genetic predisposition and environmental factors both play a role in disease.

SL: Both genetics and environmental factors have a role in the prevalence of JIA and other 'autoimmune' diseases. Greetings from Finland, a country with a 31% cumulative rate of uveitis in JIA.

KKN: I don't know if it is common in Asian countries, but genetics does play a role in terms of predisposition.

NA: It can happen in Asians, and many of my JIA patients in San Francisco are of Asian origin.

SM: JIA does not seem to be a common condition in Indiaⁱ or the Indian subcontinentⁱⁱ, the prevalence lies between 48 to 65 per 100,000. However the prevalence of uveitis due to JIA in pediatric populations appears to be fairly frequent; given that anterior uveitis accounts for almost 50% of all forms of pediatric uveitis in India, about half of these are attributed to JIA, therefore about 15-25 % of all cases of pediatric uveitis from most large eye institutes in India are due to JIAⁱⁱⁱ.

- i. Saurenmann RK, Rose JB, Tyrrell P, Feldman BM, Laxer RM, Schneider R, Silverman ED. Epidemiology of juvenile idiopathic arthritis in a multiethnic cohort: ethnicity as a risk factor. *Arthritis & Rheumatism*. 2007 Jun;56(6):1974-84.
- ii. Azam S, Dipti T, Rahman S. Prevalence and clinical pattern of juvenile idiopathic arthritis in a semi-urban area of Bangladesh. *International journal of rheumatic diseases*. 2012 Feb;15(1):116-20.
- iii. Gautam N, Singh R, Agarwal A, Yangzes S, Dogra M, Sharma A, Bansal R, Gupta V, Dogra MR, Gupta A. Pattern of pediatric uveitis at a tertiary referral institute in North India. *Ocular immunology and inflammation*. 2018 Apr 3;26(3):379-85.

10. How do you diagnose sarcoidosis uveitis in an granulomatous uveitis without lung and skin compromise to practice a biopsy?

VMU: I usually check the conjunctiva to see if any easily accessible granulomas. Pulmonary involvement is rare in younger children. We usually will do an abdominal ultrasound in addition to CXR. If you have high suspicion for the diagnosis, a high resolution CT of chest and abdomen could be considered, however, we try to avoid exposing the child to radiation by at least starting with an U/S. In addition, there may be signs of renal disease such as abnormal urinalysis and elevated urine beta-2 microglobulin or hypercalcemia. While this latter lab is classically associated with Tubulointerstitial Nephritis and Uveitis, it can also be elevated in cases any cases where renal filtration is affected. (e.g. sarcoidosis, infectious, genetic, etc.). Hypercalcemia occurs in granulomatous disorders because.

SL: Please read the comprehensive answer by VMU. An additional clinical tip: If the type of uveitis changes from anterior to intermediate or posterior uveitis, it might be sarcoid.

KKN: Look in the conjunctiva and also look to the lacrimal glands. If nothing obvious work with your rheumatology colleagues for investigations and options

NA: A CT or PET scan may help to identify other sites (i.e. lymph nodes) which could be biopsied. However, treatment does not require a definitive diagnosis, and we often use systemic therapy if the eye warrants it.

SM: In cases where phenotypical pattern in the eye leads us to a presumptive diagnosis of sarcoidosis, and S. ACE elevation, S Calcium elevation with a negative or normal Mantoux, we may ask for HRCT chest (most of the time we do not) and we work with a diagnosis of "presumed ocular sarcoidosis".

11. Any role of subtenon depot of steroids in posterior cases of JRA

VMU: Yes, there is a role. Again, I think it is important to maximize systemic, steroid-sparing immunomodulatory therapy foremost and supplement. It is important to select candidates who have not had high IOP associated with topical corticosteroid use and to monitor the patient closely after the depot. I do not use this modality often, so will defer to the others.

MHE: First is to try to control the disease according to the Uveitis management in children (immunomodulatory treatment). There is also the option to try steroids topical (durezol, or prednisolone eye drops....). If bilateral a short course of oral prednisone is also another option followed by immunomodulatory agents. Subtenon depot of steroids in macular edema is definitely an option.

SL: Yes – it can be an additional therapy in acute situations. Maybe not in bilateral uveitis. And the baseline therapy needs to be antirheumatics. The last time I had to give a subtenon injection to a pediatric patient, I also doubled their adalimumab dose from 40mg every two weeks to 40mg every week. Since then, I have first increased their antiTNF treatment and secondarily considered a subtenon or intravitreal steroid injection.

KKN: Yes, a posterior subtenons injection of triamcinolone is a definite option. If the IOP did not go up with topical steroids I have never seen it go up with a posterior subtenon injection. I use the superotemporal quadrant ; a 25 G needle that is 5/8 inch long

NA: discussed in previous questions. Can be used for macular edema. But systemic therapy is key to minimize steroids long-term.

SM: Agree with all

12. Have u came across VKH in paediatric population?

VMU: Yes, we do see paediatric VKH or Haradas. It is important to refer to audiology as sensorineural hearing loss may be concurrent and affect learning/speech.

MHE: yes, there a definitely VKH cases in children. Steroids sparing agents to be used.

SL: Not in Finland. I will defer to my colleagues.

KKN : Yes, I work with my rheumatology colleagues to treat

NA: Yes

SM: Yes, we have cases even less than 10 years of age (although rare). It is very dramatic in onset and fortunately the patients come in early for therapy. However these cases are challenging to treat and we start immunomodulators upfront in addition to IV methyl prednisolone and oral steroids (short term) for these cases.

(Sabhapandit S, Murthy SI, Singh VM, Gaitonde K, Gopal M, Marsonia K, Sajid S, Babu K. Epidemiology and clinical features of uveitis from urban populations in South India. Ocular immunology and inflammation. 2017 Aug 24;25(sup1):S39-45.)

13. Which perioperative regime do you usually advise in children who need to undergo tube surgery?

SL: Do not discontinue antirheumatics for tube surgery. And the rest depends on the patient. If they are in remission or they have low-grade uveitis SUN 0.5+, I check them 1 week prior the surgery to make sure that their uveitis is quiet/mild. Post surgically, I have them on 4-6 drops of steroids and I monitor the situation and make changes when needed.

If they have high-grade uveitis or if they have IOP rise with steroids, it gets tricky. After surgery, I monitor the inflammation and change steroid dosing depending on the level of inflammation

KKN : In conjunction with my rheum colleagues I give a tapering dose of oral steroids starting at 1mg/kg either starting 4 days before or on day of surgery.

NA: We continue all immunosuppressive therapies and supplement with peri-op oral steroids starting 3 days prior the surgery (starting at 1 mg/kg prednisone and tapering over a few weeks post-op. Aim to do a shorter taper if the inflammation is not bad.

SM: Step up or start oral steroids for short course one week prior in cases of intermediate/ pan uveitis or in those cases where I anticipate more manipulation of the iris due to dense posterior synechia.

14. How do you advise health care administrators when you see significant number of end stage blind cases in adolescent and children with bilateral pan uveitis staphyloma cataracts & nystagmus

VMU: The presence of nystagmus indicates early-onset disease. The presence of staphyloma indicates either a developmental anomaly or secondary to elevated IOP. I would be concerned about a genetic cause underlying, such as Blau Syndrome (*NOD2*-spectrum) or other autoinflammatory disorder. If genetic testing is negative, would consider an exome especially if multiple family members are affected. I would encourage the health administrators to advocate education and screening, supportive visual rehabilitation, as we try to better understand the pathophysiology of disease. I would also consider implementing screening protocols of any infant / young child with a family history of this. I would be interested to learn more details about this group of patients and see if I can collaborate with you further.

The differential diagnosis may also include disorders of wnt-signaling such as Norrie Syndrome, severe FEVR (*LRP5*, *TSPAN12*, *ZNF408*), and these disorders are bilateral, with non-regressed hyaloid. They may appear inflammatory if we do not see the natural progression. Other syndromes that fall into this category in Dyskeratosis Congenita, Pseudoglioma Osteoporosis Syndrome (*NRP5*), *KIF-11* associated, Incontinentia Pigmenti (however, systemic findings would be present with this latter disorders).

SL: Please see the answer by VMU.

Do you mean end stage blind cases because of uveitis that could have been diagnosed earlier through screening? You can start by showing them the 1988 article by Kanski: Uveitis in Juvenile Chronic Arthritis: Incidence, Clinical Features and Prognosis: "It is extremely important to screen patients at regular intervals so that the condition can be treated prior to the development of complications."

KKN : I think your question is very important; the burden of a blind child on the family and society is enormous. Try using Moorthy LN, Peterson MG, Hassett AL, Lehman TJ. Burden of childhood-onset arthritis. *Pediatr Rheumatol Online J*. 2010 Jul 8;8:20. doi: 10.1186/1546-0096-8-20. PMID: 20615240; PMCID: PMC2914068.

SM: We do not really have much of a systematic coordination from the government agencies at this point. Advocacy for this for policy making is at its infancy.

15. How does one tail off (how fast, how much) the adalimumab after the inflammation in eyes / joints are totally controlled?

VMU: Please refer to the response for question 1. In general, 2 years or more. Some physicians will taper adalimumab by spacing the medication out > 2 weeks, while others will just discontinue it completely. We are still learning and multi-centre, international studies are truly needed to guide us.

SL: I do not recommend reducing the dose before discontinuing. Anti-drug antibodies are common in this disease and you put the patient at high-risk of producing anti-drug antibodies with tapering dosing. I have not successfully discontinued adalimumab without creating a high-grade relapse. Please see question 1 and 8. Follow ADJUST study. Leinonen ST et al. Anti-adalimumab antibodies in juvenile idiopathic arthritis-related uveitis. *Clin Exp Rheumatol*. 2017;35(6):1043-1046 Acharya NR et al. Discontinuing adalimumab in patients with controlled juvenile idiopathic arthritis-associated uveitis (ADJUST- Adalimumab in Juvenile Idiopathic Arthritis-associated Uveitis Stopping Trial): study protocol for a randomised controlled trial. *Trials*. 2020 Oct 27;21(1):887.

KKN : I leave this to my rheum colleagues and advise on the state of the eyes

NA: Same as above. I don't taper adalimumab. I just try to stop after 2 year or more. We are trying to learn more about this in the ADJUST Trial.

SM: Usually take the opinion of our rheumatology colleagues

16. Any feed-back on the use of laser-flare photometry in these patients?

VMU: Yes, I think flare is an important component of disease and maybe an important consideration when a patient is stopping treatment. A laser-flare photometer is on my wish-list at my institution, as we do not have one at this time. AS-OCT also holds promise in correlating to flare photometry.

MHE: Very useful. Reference: Laser Flare Photometry: A Useful Tool for Monitoring Patients with Juvenile Idiopathic Arthritis-associated Uveitis. Orès R, Terrada C, Errera MH, Thorne JE, Doukhan R, Cassoux N, Penaud B, LeHoang P, Quartier PM, Bodaghi B. Ocul Immunol Inflamm. 2020 Aug 24:1-11

SL: Elevated laser flare seems to be its own risk factor among JIA-uveitis patients although higher laser flares associate with higher SUN grades. Tappeiner C. Elevated laser flare values correlate with complicated course of anterior uveitis in patients with juvenile idiopathic arthritis. Acta Ophthalmol (Copenh). 2011;89(6):e521-e527.

KKN: Never used one, but will definitely get one now.

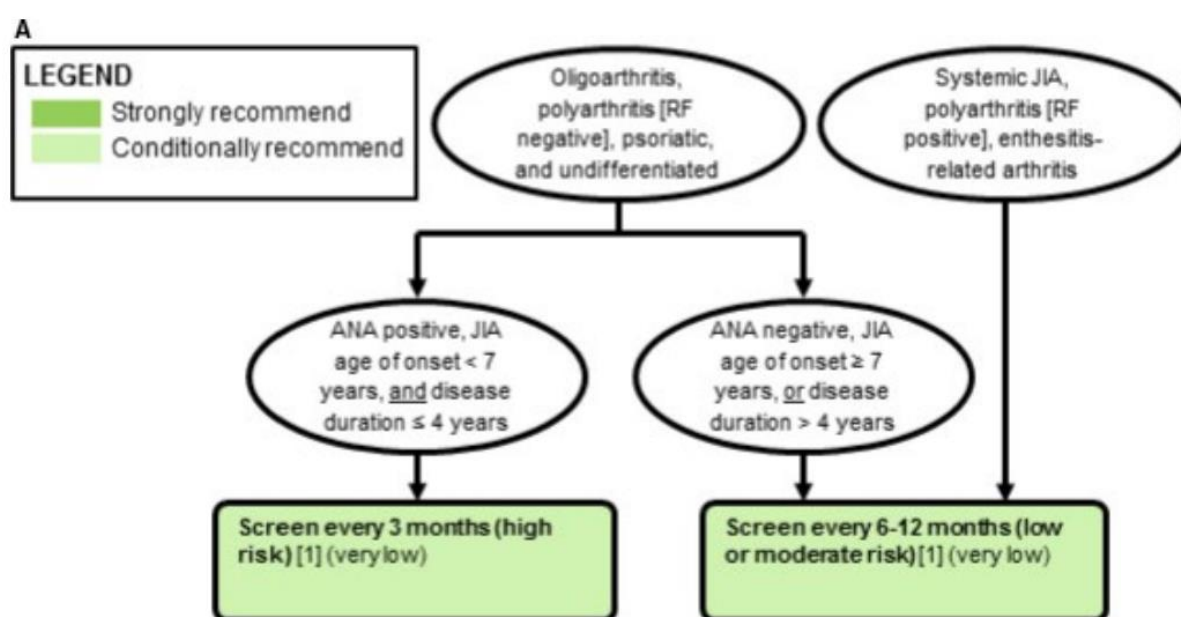
NA: We don't have one but it may be useful in tracking response to treatment and recurrence. Our French uveitis colleagues (see comment from MHE) have studied this.

SM: We had used one for another study a while ago. I think there are some technical challenges and test-retest variation in getting the readings from the machine we had in the past. But it does hold utility.

17. What protocol do you follow for screening for uveitis in JIA patients. Every 3 months or every 6 months? Does age of onset of JIA and ANA/Rf positivity affect the frequency you screen for uveitis?

VMU: Here are the screening guidelines that we use. A new American Academy of Paediatric Screening Guideline for JIA will be published in the very new future. Please stay tuned and we will send out the reference as soon as it is published.

ANGELES ST



Screening Algorithm for Uveitis in Children with JIA (Figure 1A., Angeles-Han ST, Arthritis Care & Research, 2019, 71 (6), 703-716.)

MHE: 2019. American College of Rheumatology/ Arthritis for the screening, monitoring, and treatment of JIA associated uveitis.

SL: We follow a modified guideline by Heiligenhaus et al but are considering some modifications to it. Heiligenhaus A, German Uveitis in Childhood Study Group. Prevalence and complications of uveitis in juvenile idiopathic arthritis in a population-based nation-wide study in Germany: suggested modification of the current screening guidelines. Rheumatology. 2007;46(6):1015-1019.

Table 3. Screening guideline for JIA-uveitis in Finland

Oligoarthritis, extended oligoarthritis, polyarthritis RF -, psoriatic arthritis, other arthritis					
Years from diagnosis (max 16 years of age)	≤6 years of age at the diagnosis			>6 years of age at the diagnosis	
	ANA+		ANA-	ANA+	ANA-
0-2		3 months		6 months	
2-4	3 months		6 months		
4-7	6 months	6 months		12 months	12 months
>7	12 months	12 months	12 months		
Control at 3-6 months if antirheumatic therapy is discontinued					

Enthesitis-related arthritis, polyarthritis RF+, systemic-onset arthritis	
Every 12 months until 16 years of age	
Control at 3-6 months if antirheumatic therapy is discontinued	

KKN: I use the AAO guidelines . I think Dr Utz has them displayed

NA: I follow the same recs. as VMU

SM: We do not have a robust system in place yet. Follow up of asymptomatic patients is a challenge.

18. With PIC do you see CNVM as in adults

VMU: Will defer to my colleagues.

MHE: PIC always strongly associated with CNVM

KKN: If I make the diagnosis I refer to retina and now Dr. Errera as she works with me now at my children's hospital

NA: I have not seen PIC in children, only in adults. But we definitely see CNVM in PIC.

SM: Defer to retina colleagues

19. What's your choice for kids who get side effects with Methotrexate and who won't allow any injectable biologicals?

VMU: Usually, we sometimes recommend consultation with a behavioural specialist to develop coping strategies for dealing with needles. Infliximab or golimumab are also both available by infusion, and could be considered. In terms of non-biologic DMARDs, sometimes mycophenolate or leflunomide (both oral) are used.

SL: Azathioprine 2-3mg/kg/day for patients without a TPMT mutation or mycophenolate 600mg/m²/day.

KKN: Defer to my Rheum colleagues

NA: Behavioural modification/counselling can help, but if not, then infusions are a great option and are better tolerated by kids (they usually don't feel anything). Infliximab is a good option.

SM: Did not have such cases yet

20. For surgical interventions, does the panel implant IOLs and put in tubes when needed for glaucoma?

VMU: The approach to surgery is based on patient and disease characteristics. Glaucoma can be treated by a tube or angle surgery. Again, some patients will not need glaucoma surgery after systemic steroid-sparing treatment is augmented, as the intraocular pressure improves to a satisfactory pressure once topical corticosteroids are discontinued.

SL: IOLs are routinely implanted in eyes with JIA-uveitis in Nordic countries. We insert primary IOLs at cataract surgery with or without anterior vitrectomy. I would consider aphakia in eyes with uncontrolled uveitis and/or ocular hypotony.

Kulik U et al. Long-term results after primary intraocular lens implantation in children with juvenile idiopathic arthritis-associated uveitis. *Eur J Ophthalmol*. 2019 Sep;29(5):494-498.

Leinonen et al. Results 5 to 10 years after cataract surgery with primary IOL implantation in juvenile idiopathic arthritis-related uveitis. *J Cataract Refract Surg*. 2020 Aug;46(8):1114-1118.

Tube shunts and trabeculectomies are the most common glaucoma operations for JIA-uveitis-related glaucoma in Europe. My clinical preference: trabeculectomy for eyes with well-controlled uveitis and tubes for eyes without good control of uveitis.

Leinonen S. Potential effect of tumor necrosis factor inhibitors on trabeculectomy with mitomycin C for patients with juvenile idiopathic arthritis-related uveitic glaucoma: a retrospective analysis. *JAMA Ophthalmol*. 2015;133(11):1323-1328.

KKN: This is a VERY complicated question: always think about the future of the child. For glaucoma use goniotomy first if possible. Then think is this child going to end up having cataract surgery and if so, how likely are we to be able to place an implant. If the child is going to be aphakic then a tube is a necessity because the child can then wear contact lenses when older (not possible if a trabeculectomy is done).

For IOL control must be good for at least 12 months in my book. Then when the surgery is done, posterior rhexis must be done; anterior vitrectomy with intravitreal triamcinolone (triamcinolone) and anterior chamber dexamethasone.

NA: Lots to say on this topic, but we do recommend an IOL if inflammation has been well-controlled, particularly on immunosuppressive therapy. If IOP cannot be controlled or a patient is requiring long-term maximal medical therapy, we recommend glaucoma surgery. Usually, a tube is the first choice at our institution.

SM: I defer to my colleagues for tubes. For IOLs, many of our patients do not present to us in the early part of the disease, we see them at the stage of complicated cataracts with dense pupillary membranes, BSKs, some may even be in hypotony. For such cases we prefer posterior approach and leave them aphakic. For well controlled disease with no complications, we routinely use IOLs. A general cut-off of age (less than 10) is also considered for implantation of IOLs, as in our experience we have seen poor results due to continuing inflammation. We are underway studying our cases and hope to publish these results soon.

21. Can you share your protocol for oral fluorescein angiography with everyone?

VMU: Oral FA: Need to do an informed consent and weigh the patient.

- Weigh the patient

< 45 kg → 5 mL fluorescein

> 45 kg → 10 mL fluorescein

- Mix fluorescein with 6 oz of apple juice & have child drink through straw
- Check at 5 minutes to see if image intensity is adequate (usually can see fluorescein from 5-15 minutes)
- If NPO, can see fluorescein earlier

KKN: we are just publishing this so it will be available in the next couple of months

SM: Not done at our center currently.

22. Do you use Latanoprost in Uveitic glaucoma?

VMU: It is not the first medication that I use, but certainly a consideration for treatment.

SL: Yes. My go-to topical medication is dorzolamide or brinzolamide with timolol and second line is latanoprost or other prostaglandin analogues. I have not seen a uveitis relapse in a uveitis patients after introducing prostaglandin analogues.

KKN: I will use it but not first line

NA: I don't use it first-line but do not hesitate to add it if needed for IOP control

SM: Agree with above

23. What is your threshold to start oral prednisone for acute uveitis? Should we routinely start oral steroids if papillitis? and if you start steroids, what dose and what is goal for total oral steroid use

VMU: Sometimes mild papillitis will resolve with treatment of the anterior segment with topical eye drops alone. Other times oral steroids or steroid-sparing treatment is needed. If any findings consistent with optic neuropathy, need to do a thorough work-up and consult with neuro-ophthalmologist/neurologist. . If I do start someone on oral steroids, I usually use 1 mg/kg and try to taper over 3-4 weeks. The goal is to minimize oral steroid exposure, so disease that recurs upon tapering of oral steroids is an indication for systemic treatment escalation. For severe acute anterior uveitis (such as that associated with HLA-B27 positivity), sometimes difluprednate at high frequency is needed or oral steroids. I monitor the intraocular pressure on a weekly basis while on difluprednate.

MHE: I would say it depends. If papillitis related to severe anterior uveitis, I would treat the anterior uveitis first only because the papillitis might resolve. I would perform a fluorescein angiography if isolated papillitis in case this is associated with pars planitis or retinal vasculitis. If pars planitis with no alteration of vision and normal visual fields, we can observe. If retinal vasculitis or pars planitis with reduction of vision and visual fields, I would consider a short course of oral steroids or periocular steroids and a low threshold for a steroid sparing agent if chronicity

SL: I agree with VMU regarding systemic steroids. Remember to check their serum cortisol levels before discontinuing systemic steroids.

If there is a high-grade of inflammation in acute uveitis, the disease associates with a higher risk of vision loss and relapsing and as such, you should also consider antirheumatic treatment to control the uveitis in the future.

KKN: I can't remember starting oral steroids for anterior uveitis; I prefer giving periocular steroids if acute initial presentation (infection having been excluded). With posterior involvement it is an option but again for me a conversation with my rheum colleagues gives us a road map to follow

NA: The papillitis associated with anterior uveitis almost always improves with topical steroids. Severe vit haze, vasculitis or retinal/choroidal inflammation benefits from oral prednisone starting at 1 mg/kg, but we try to use steroid-sparing therapy in these cases long-term.

SM: Apart from the points already covered above, oral steroids for intermediate/ posterior/panuveitis, at 1mg/kg. Mostly as bridging therapy, till the upfront immunomodulators start working (takes 2-3 months). In anterior uveitis, if complicated with hypotony or perioperatively.

24. How often would you follow a patient after stopping treatment - to monitor recurrence?

VMU: This depends on the medication. For methotrexate, I may monitor at 8 weeks, whereas with a biologic, I may see the patient back in 4-6 weeks.

SL: In JIA-uveitis, I see patients every 6-8 weeks after discontinuation.

I expect to see relapses after 3 months from discontinuing methotrexate after 2 years of remission without topical steroids. I expect to see a high-grade relapse at 6 months at the latest after discontinuing antiTNF treatment. I never discontinue antiTNF without keeping the patient on a DMARD medication such as methotrexate.

Please check the answers in questions 6 and 8.

Kalinina Ayuso V et al. Relapse rate of uveitis post-methotrexate treatment in juvenile idiopathic arthritis. Am J Ophthalmol. 2011 Feb;151(2):217-22. doi: 10.1016/j.ajo.2010.08.021.

KKN: in conjunction with Rheum colleagues

NA: Agree with the above timings.

SM: Same as above

25. Does any of the panellists' have some experience with Nrf2 activators as inflammation control adjuvants in Rheumatoid Arthritis?

VMU: I do not, but I will certainly research it.

MHE: No I do not.

SL: No

KKN: No

NA: No

SM: No

26. Any role of topical NSAIDS in steroid responders with JIA?

VMU: No, I do not use topical NSAIDs. However, if I am able to taper to lower potency steroids such as (FML 0.1%, FML Forte, Lotemax), sometimes the IOP issues resolve, while still keeping the inflammation controlled.

SL: No

KKN: No

NA: No

SM: While I do use topical NSAIDs, they at best help in maintenance therapy always along with low potent steroids, but in case of steroid responders, I would resort to systemic immunomodulators

27. With papillitis should we routinely obtain an IVFA? is there any role of neuro imaging for papillitis in the setting of uveitis?

VMU: Very mild papillitis is extremely common in new onset anterior disease, and usually does not require imaging. At baseline, I always check for an APD (unless they come in on cycloplegic medications), check color and contrast discrimination. I will also order a baseline visual field in older kids and document with OCT RNFL. If there are any other neurologic symptoms or signs of an optic neuropathy, I will consider neuroimaging. While I expect leakage from the disc on FA (IV or oral), I will order an FA to evaluate for any other subtle posterior segment vascular findings.

MHE: Yes, I would obtain an oral FA with papillitis to rule out a retinal vasculitis, MEWDS etc. & Brain MRI to exclude MS.

SL: Papillitis is not that uncommon in anterior uveitis and as such, I first treat and then see if I need an FA. I use OCT for monitoring the optic disc and peripapillary area are in these patients.

If there are other neurologic symptoms, a family history of MS, if the papillitis does not subside, I will order an MRI.

KKN: yes with oral FFA I have a lower threshold to do FFA

NA: I would recommend an FFA (oral fine) to evaluate for vascular leakage or other pathology because this can change management.

SM: I have not very commonly seen papillitis in acute anterior uveitis, will look for it henceforth